

V. JOTAUTAS¹, E. POSKUS¹, P. ZEROMSKAS¹, D. SEININ², K. STRUPAS¹

TREATMENT OF RECTAL TUMOURS WITH TRANSANAL ENDOSCOPIC MICROSURGERY: SIX YEAR'S EXPERIENCE IN LITHUANIA

Vilnius University Hospital «Santariskiu Klinikos»¹,
National Center of Pathology²,
Lithuania

Цель исследования: оценить шестилетний литовский опыт применения в трансанальной эндоскопической микрохирургии для лечения опухолей прямой кишки в центре абдоминальной хирургии клиники Вильнюсского университета «Santariskiu Klinikos».

Материал и методы. Для оперативного лечения были отобраны пациенты с аденомами прямой кишки и опухолями T1 с низкой степенью злокачественности хорошо или среднедифференцированными, без признаков поражения лимфатических узлов и сосудистых структур. Стадия опухолевого процесса устанавливалась до оперативного вмешательства при помощи трансанальной эндоскопии, магнитно-резонансной томографии и ректороманоскопии с проведением множественной макробиопсии.

Результаты. Было прооперировано 155 пациентов, которым проведено в общей сложности 161 трансанальное эндоскопическое микрохирургическое вмешательство (TEM) с удалением 172 опухолей. Средний размер опухоли составил $3,17 \pm 1,93$ см (размеры варьировали от 0,3 см до 12 см). Всего было удалено 60 (33,7%) злокачественных опухолей и 106 (59,9%) аденом. Предоперационный и окончательный диагноз не совпали у 24 (13,9%) пациентов. Из выполненных операций 154 (89,5%) были проведены радикально (R0), одна операция (0,6%) – нерадикально (R1), радикальность ещё 17 операций (9,9%) неизвестна (RX). Осложнения отмечены в трёх случаях (1,9%). Пяти пациентам из девяти оперированных по поводу карцином T2 была проведена адьювантная лучевая терапия. Отдалённые результаты лечения в сроки от 2 до 44 месяцев прослежены у 132 пациентов. У 2-х пациентов (1,2%) возник рецидив тубуловорсинчатой аденомы, ещё в одном случае (0,6%) диагностирована карцинома Tis. Других осложнений отмечено не было.

Заключение. При использовании трансанальной эндоскопической микрохирургии для лечения аденом прямой кишки и карцином T1 с низкой степенью риска (злокачественности) получены хорошие результаты. Низкая частота осложнений и рецидивов в указанной группе даёт большие надежды. Опыт использования трансанальной эндоскопической микрохирургии в сочетании с адьювантной лучевой терапией для лечения карцином T2 пока невелик, но полученные результаты поддерживают развитие данного направления. Для окончательных выводов необходимо дождаться результатов рандомизированных контролируемых исследований.

Ключевые слова: опухоли прямой кишки, мининвазивная хирургия, трансанальная эндоскопическая микрохирургия

Objective. The aim of this study is to assess six year's experience gained in Lithuania while treating rectal tumours with transanal endoscopic microsurgery in the Centre of Abdominal Surgery of the Vilnius University Hospital «Santariskiu Klinikos».

Materials and methods. Patients having rectal adenomas and low-risk malignant tumours of stage T1, good or medium differentiation, with no lymphatic and vascular invasion were chosen for operations. The stage of the tumour has been determined before the operation after transanal endoscopy, MRI and rectoscopy with multiple macrobiopsies.

Results. 155 patients were operated, 161 TEM were performed and 172 tumours were removed. The median size of tumours was $3, 17 \pm 1,93$ cm (ranged from 0,3 to 12 cm). Overall 60 (33,7%) malignant tumours and 106 (59,9%) adenomas were removed. Pre-operative and final clinical diagnoses did not

coincide for 24 patients (13,9%). 154 (89,5%) radical operations (R0), 1 (0,6%) not radical (R1) and 17 (9,9%) operations of unknown radicality (RX) were performed. Three (1,9%) complication were observed. After the removal of nine Ca T2 five patients underwent adjuvant radiotherapy. 132 patients were followed-up for 2–44 months after the operation. Two (1,2%) recurrence of a tubulovillous adenoma and one of a CaTis (0,6%) was diagnosed. No other complications were reported.

Conclusions. The results of transanal endoscopic microsurgery obtained while treating rectal adenomas and low-risk T1 cancers are good. The low rate of complications and recurrences in this group offers much hope. The experience of the treatment of T2 cancers with transanal endoscopic microsurgery and adjuvant radiotherapy is limited but the results are encouraging. The results of randomised and controlled trials need to be awaited before definite conclusions can be drawn.

Keywords: rectal tumours, minimally invasive surgery, transanal endoscopic microsurgery

Introduction

Rectal cancer still remains a major problem. Every year around 700 new cases of malignant rectal tumours are revealed in Lithuania. According to the Lithuanian Cancer Register of 2008, 685 new cases were registered, 95 of them of the first stage and 185 of the second one. Rectal cancer develops from epithelial dysplasias. More than 95% of all dysplasias progress to adenomas. According to the autopsy data of patients aged over 60 years, 10–20 % of adenomas are found in the rectum. Currently, in Europe transanal endoscopic microsurgery (TEM) is considered to be the standard radical operation of large rectal adenomas and low-risk T1 malignant tumours [1, 2].

It is a minimally invasive surgical approach combining the advantages of local resection, low complication rate and the least inconvenience to patients. Compared to other operations of local excision: transsacral, transphincter or transanal (using the Parks' retractor) approach, TEM offers the possibility of removing tumours from the entire rectum especially thoroughly and safely and ensures high visibility while performing excision of tumours without causing healthy tissue damage.

The aim of this study is to assess six year's experience gained in Lithuania while treating rectal tumours with transanal endoscopic microsurgery in the Centre of Abdominal Surgery of the Vilnius University Hospital

«Santariskiu Klinikos».

Patients and methods

Statistical analysis of data. The data was processed using the statistical package "Statistica 5,0". Methods of descriptive statistics and correlation analysis applying a Spearman's coefficient were used for the evaluation of parameter data.

Model of the study. The first TEM in Lithuania, based on Buess methodology, was performed at the Vilnius University Hospital "Santariskiu Klinikos" in 2003. As for 30 September 2009 161 TEM operations were performed. This article analyses the results of all 161 cases treated in accordance with the TEM technique. Patients having rectal adenomas and low-risk malignant tumours of stage T1, good or medium differentiation, with no lymphatic and vascular invasion were selected for operations. The stages of tumours were determined preoperatively, having performed transanal endoscopy, magnetic resonance imaging (MRI) and rectoscopy with multiple macrobiopsies. Every patient underwent sonoscopy of abdominal organs and fibrocolonoscopy. During operations an operative rectoscope made by the Richard Wolf Company with a three-dimension optical system and 6 times magnification was used. The following parameters were evaluated: accuracy of a preoperative diagnosis in comparison to final pathohistological findings,

as well as the size and location of the tumour, operating time, loss of blood, period of hospitalisation, complications and follow-up data obtained following 2–44 months after the surgery.

Preoperative preparation of the patient includes the following: before surgery the intestine underwent orthograde lavage (with 3 l of Fortrans solution). In the morning before surgery, having determined that the intestine had not been sufficiently cleaned, additional cleaning enemas were made. For the antibacterial prophylaxis, 30 min prior to the operation one intravenous infusion of 1,5 g of Zinacef and 500 mg of Metronidazoli was made. All operations were performed under the conditions of general endotracheal anaesthesia.

Transanal endoscopic microsurgery.

Since the optic of the operative rectoscope has of an angle of 40°, during TEM the tumour is in 4–8 o'clock position, therefore, before the operation, the patient is positioned according to the tumour location in a lateral right or left position, a lithotomy or prone position and tightly fixed. After gentle extension of the sphincter, the TEM operative rectoscope is inserted. Local excision of the tumour is performed after distension of the rectal cavity by pressure-controlled CO₂ insufflation up to 15 mm Hg pressure. The operation is started by marking an inclusion line with coagulation points around the tumour by a monopolar electrode. It is attempted that a safe distance would be kept from the tumour to the incision line: a distance of 0,5 cm when removing adenomas and of 1 cm when removing malignant tumours. Depending on the tumour location and its histological form, mucosectomy, partial or full excision of the wall, is performed. It is sought to meet the requirements of the safe TEM technique: all tumours located in the extraperitoneal part of the rectum are removed by means of excision of all wall. After a thorough hemostasis and treatment of the wound with a physiological

and chlorhexidine solution, it is sutured by SH needle with 3-0 PDS thread. In case of perforation of the peritoneum, the defect is sutured with the same 3-0 PDS thread. Silver clips serve as nodes. 160 TEM operations were performed using a high-frequency electro-knife; one of them was performed using an ultrasound dissector. Using an ultrasound dissector, the operation is safer and the operating time is shorter.

Results

155 patients were operated: 67 (43,3%) men and 88 (56,7%) women. The median age was $66,7 \pm 11,28$ years (ranged from 35 to 92 years).

Tumour location was preoperatively determined during rectoscopy when a patient was lying in a lithotomic position. The distance from the distal margin of the tumour to the linea anocutanea as well as the tumour location in respect to the circumference of the rectum were assessed. Assessment was carried out in respect to the location: the lower (≤ 5 cm), the middle (6–11 cm) or upper (12–16 cm) third of the rectum; the anterior, posterior, left or right lateral wall. The majority of tumours were located in the middle third of the rectum – 28,1%, while others were located in the lower third – 27,5% and the upper third – 26,4% (Fig. 1). The most common location in respect of the circumference was the posterior wall – 36 %, other tumours were located in the anterior wall – 25%, the left lateral wall – 11 cases (22,9%) and the right lateral wall – 18,8% (Fig. 2).

Removed tumours. After the recession of a tumour, it was fixed to a cork board and measured; a photograph of preparation was taken (Fig. 3, 4, see color sheet). The largest dimension of a tumour was determined. The mean tumour size was $3,17 \pm 1,93$ cm (ranged from 0,3 to 12 cm).

All tumours described in this article were

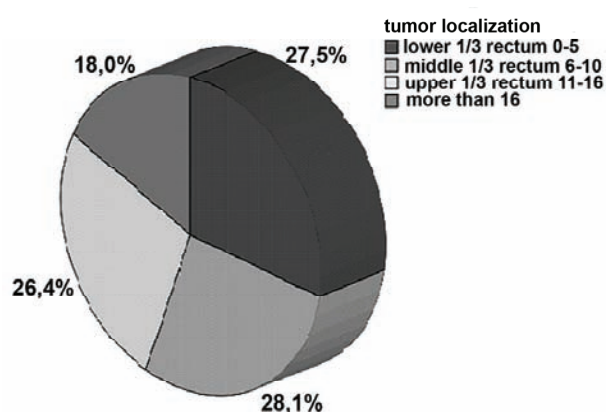


Fig. 1. Tumour location according to height

evaluated by the same pathologist and divided into stages according to the TNM classification. After the fixation of the tumour to the cork board, margins of excision were assessed. The removal of the tumour and possible damage of healthy tissues were assessed in terms of radicality, i.e. complete resection (R0), incomplete resection (R1) and doubtfully complete resection (RX). Doubtfully complete operations belong to those during which the tumour with unclear margins is removed or it is resected not in toto but in pieces so the pathologist cannot evaluate the resection margins.

60 (33,7%) malignant tumours and 106 (59,9%) adenomas were removed. There were 37 Ca Tis (61,7%), 14 Ca T1 (23,3%) and 9 Ca T2 (14,9%) found among malignant tumours (Table). Tubulovillous adenomas predominated among adenomas, as there were found 87% of

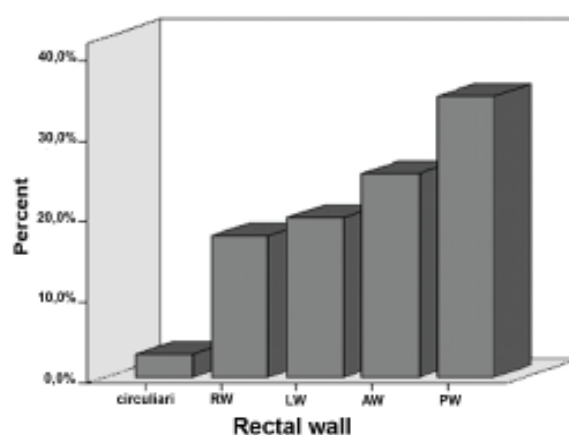


Fig. 2. Tumour location according to circumference

them.

154 (89,5%) operations of radical resection (R0), 1 (0,6%) not radical (R1) and 17 (9,9%) operations of unknown radicality (RX) were performed. All tumours the radical removal of which was doubtful were large adenomas of 5–7 cm in size. They were removed by solid preparations; however, due to the size of tumours and uneven margins of the removed part of the rectum a pathologist could not evaluate the level of radicality accurately.

Preoperative and final clinical diagnoses, compared after the pathohistological examination of the removed tumours, did not coincide for 24 patients (13,9 %). After the final histological examination of 131 tumours that were preoperatively diagnosed as tubulovillous adenomas 24 Ca were found. All these tumours were large adenomas of 2–7 cm

Table

Diagram of tumours removed with TEM technique

Diagnosis (n = 178)	Preoperative diagnosis		Postoperative diagnosis	
	n	%	n	%
Adenoma	131	73,6	106	59,9
Adenocarcinoma	36	20,2	60	33,7
Carcinoid	2	1,1	2	1,1
Polyp	2	1,1	3	1,7
Stricture	6	3,4	6	3,4
Ba-granuloma	1	0,6	1	0,6

in diameter. Only after an accurate pathological examination, intramucous or even invasive T1 malignant tumours were found in their central parts. After the operation, one Ca Tis turned out to be Ca T1, one Ca Tis – Ca T2 and two Ca T1 – Ca T2. The above mentioned tumours were removed by full resection of the wall; the conclusion of the final pathohistological examination was radical removal. Therefore, additional interventions were not applied to the patients whose diagnosis showed that they had Ca Tis or Ca T1 and they were followed-up further. It was recommended to perform repeated operations (anterior rectal resection) to three patients, the diagnosis of who showed that they had Ca T2 G1-2 after TEM. All three patients refused to undergo the operations, thus, they received radiotherapy. The fourth case of Ca T2 removal was a radical removal of a tumour of 4 cm in diameter performed to a 92-year-old man who also had a parallel cardiologic pathology (ASA-III). After 4 days the patient was discharged from the hospital. Complications were not reported. Due to old age and parallel pathology, adjuvant radiotherapy should be contraindicated. A patient has been followed-up for one year and no complications occurred.

Postoperative follow-up of the patient.

After the removal of an adenoma, a patient is recommended to come for examination every six months, and every three months after the removal of a malignant tumour. 132 patients were followed-up 2–44 months after the operation. Complaints of patients and faecal continence were assessed, digital examinations and rectoromanoscopies performed. CEA and Ca 19-9 examinations, sonoscopy of abdominal organs, transanal endosonography, MRI were performed to patients who underwent operations of malignant tumours as well as during rectoromanoscopy multiple biopsies were taken from the places of operative scars. Two (1,2%) recurrence of a tubulovillous adenoma and one of a CaTis (0,6%) was

diagnosed and treated with a repeated TEM. Patients had no complaints and no complications were found.

Operative time. The duration of an operation was calculated from insertion of the operative rectoscope till its withdrawal. The mean operating time was $70,13 \text{ min} \pm 46,26 \text{ min}$. Operating time became shorter and shorter as the operating skills improved. After the correlative analysis of non-parameter dimensions, a direct medium-strong relation between operating time and the size of a tumour was found (Pirson coefficient 0,540; $p < 0,001$). Thus, the duration of TEM is determined by the tumour size as well. TEM duration becomes shorter when an ultrasound dissector is used.

Blood loss. During all operations blood loss was minimal, i.e. 0–30 ml.

Period of hospitalisation. Patients were hospitalised one day prior to the operation. The median period of hospitalisation was $3,9 \pm 0,8$ days. First 20 patients were followed-up after operations longer as a new operative technique was being mastered.

Complications. After 161 TEM operations, three patient suffered three complication (1,9%). After the removal of an adenoma, which was 6 cm in diameter, located 13 cm from the linea anocutanea at 4–9 h and covering almost half the circumference of the rectum, peritonitis was diagnosed clinically on the following day. After the radiological examination, free air was found under the diaphragm. The patient was operated and laparotomy was performed. Only pneumoperitoneum and an impermeable TEM suture were found in the intraperitoneal part of the rectum, the rectovesical recess. This place was drained. On the following day the drain was removed. The patient recovered without having any complications. During the operation a complication occurred in two patients. When removing a Ca T1 of 3 cm in diameter, located 13 cm from the linea anocutanea at 2–4 h, the peritoneum was opened. It was sutured and the

operation was proceeded by TEM. The tumour was removed radically (it was verified pathohistologically). The two patients recovered without having any complications.

Discussion

Rectal cancer still remains a major problem. A standard anterior resection of the rectum and abdomino-perineal resection remain the «gold standard» for radical operations of rectal cancer. During anterior resections and abdomino-perineal resections a dissection of pelvic tissues, which is related to the risk of pelvic nerve damage, is performed. The death rate after anterior resections ranges between 1–7% [3, 4].

It is higher among patients over 75 years of age [5]. 15% of patients after an abdomino-perineal resection become impotents, and 10% of patients suffer from ejaculatory dysfunction [6, 7]. Urinary dysfunction is also quite common: about one third of patients suffer from urinary continence, therefore additional operation is often performed [6, 7].

Technical progress raises the interest in local treatment of benign and malignant rectal tumours. As the number of elderly patients increases, methods of local treatment of rectal tumours become more and more important. A decision on the type of operation to be performed depends on the resectability and the risk level of recurrence of a tumour. This is mainly determined by the stage of a tumour. Hermanek and Gall, while examining patients who had T1 tumours of < 3 cm in diameter, of G1 or G2 differentiation and no lymphatic and vascular invasion, found only 3% of lymph node metastases [8]. According to the data of other authors, this percentage rate increases to 11–12% [9]. According to present recommendations, tumours that can be removed by local excision have to comply with the above mentioned criteria. Such tumours are considered to be low-risk tumours. At present

local excision operations of rectal tumours, such as transsacral or transphincter excision, are not performed due to a high rate of postoperative complications (faecal fistulas, faecal incontinence).

Operations of the rectum while using retractors are not convenient. In the course of the operations, the field of visibility is restricted by retractors themselves, surgical instruments and hands of the surgeon. The part of the rectum above retractors contracts and, thus, reduces the visibility of the operating area. For these reasons, a transanal operation is possible only in case of pathology of the lower and partially middle third of the rectum. The advantage of TEM, if compared to other operation of local excision, is determined not only by a very good view of the operative area, precise and safe removal of a tumour but also by a possibility to safely remove tumours located in the middle and upper third of the rectum. 26,4% tumours removed by us were located in the upper third of the rectum. Tumours located in this height are impossible to reach when performing a local transanal excision. According to different authors, the rate of TEM complications (conversion to laparotomy, bleeding, perforation of sutures, rectovaginal fistulas, temporary faecal incontinence or urinary continence) reach 7–13% [10, 11, 12], however, only 5–6% of patients need additional operation [13, 14]. The number of complications of traditional transanal operations is higher and reaches 0–14,5% [15, 16].

After 161 TEM operations, one patient suffered a constant complication, i.e. postoperative pneumoperitoneum. CO₂ gas appeared in free abdominal cavity during TEM: while suturing wound of a removed tumour, the intraperitoneal part of the rectum in the rectovesical recess was affected too. The reason was determined during laparotomy. The patient recovered. In this case, diagnostic laparoscopy would have been sufficient.

3–4% patients who undergo TEM suffer from faecal incontinence; this function usually recovers within 4–5 months [13]. We have not encountered this complication in our clinical practice. In our opinion, one of the possible reasons for that are cautious and sphincter-sparing manipulations of a rectoscope during operations.

Buess states that fever occurring after TEM is related to suture leakage, i.e. the phenomenon which is common in one third of patients [17, 18]. According to Lloyd, a small defect of extraperitoneal anastomosis was found in 12 of 30 patients who suffered from a temporary fever lasting for 1–2 days [19]. When the intestine is poorly prepared for operation, some surgeons wishing to reduce risks of abscess occurring behind the rectum leave the defect of anastomosis [20] on purpose or does not suture it at all. In their opinion, this defect does not cause any short-term or long-term outcomes.

We sutured wounds of all removed tumours. Good preoperative bowel cleaning is of special importance. Before suturing the wound, we clean the defect with physiological and chlorhexidine solutions. That may be the reason for absence of fever and suture leakage in all patients. Attempts to find data about similar treatment of wounds in medical literature failed. Clear margins of the removed tumour are especially important in determining the stage of cancer and radicality of local excision. A close cooperation of a surgeon and a pathologist is needed in order to make preparation ready for use and assessed. All tumours removed in our clinic during TEM were examined by the same pathologist.

We performed 154 (89,5%) radical operations (R0). 17 (9,9%) adenomas were removed by a resection of unknown radicality (RX). Since the adenomas were benign tumours, additional interventions were not applied to the patients and they are followed-up further. All malignant tumours were removed

radically.

The final pathohistological examinations showed that 13,9% of adenomas were intramucous or event T1 cancers. The data obtained by us meets the requirements of a safe TEM: it is necessary to remove all tumours that are in the extraperitoneal part of the rectum in accordance with the principles of oncological excision.

The recurrence rate for both benign and malignant tumours is lower while performing TEM (2,5–14%), if compared to usual transanal excision (9,4–27,3%) [11]. It reaches 1,8 % for patients operated by us (three patient). Thirteen T1 malignant tumours removed by us were low risk, thus, radiotherapy was not applied.

Currently, many TEM clinical studies related to treatment of T2 tumours with radiotherapy are being conducted. Since the data of late follow-ups is not available yet, sources of literature claim that the use of TEM may be justifiable only in those cases when a patient is elderly (over 75 years), has parallel pathology or refuses to undergo an open operation [1].

After the removal of a T2 malignant tumour, adjuvant radiotherapy (50 Gy) was applied to five of nine our patients. They have been followed-up and recurrences have not been reported yet. As a period of follow-up is short, no conclusions can be reached.

Conclusions

Transanal endoscopic microsurgery improved the possibilities of local excision operations of rectal tumours. The Vilnius University Hospital «Santariskiu Klinikos» is the only clinic in Lithuania where transanal endoscopic microsurgery is performed. The results of transanal endoscopic microsurgery obtained while treating rectal adenomas and low-risk T1 malignant tumours are promising. The low rate of complications and recurrences

in this group offers much hope. The experience of the treatment of T2 cancers with transanal endoscopic microsurgery and adjuvant radiotherapy is limited but the results are encouraging. It is obvious that the results of randomised and controlled trials need to be awaited before definite conclusions can be drawn.

REFERENCES

1. Buess, G. Technik und Indikation zur sphinktererhaltenden transanal Resektion beim Rectumcarcinom. (Technique and indication for the transanal resection of carcinomas of the rectum) / G. Buess, J. Kayser // *Chirurg.* – 1996. – Vol. 67. – P. 121-128.
2. Transanal endoscopic microsurgery (TEM) for minimally invasive resection of rectal adenomas and «low-risk» carcinomas (uT1, G1-2) / C. Langer [et al.] // *Gastroenterol.* – 2002. – Vol. 40. – P. 67-72.
3. Ohman, U. Colorectal carcinoma-trends and results over a 30-year period / U. Ohman // *Dis. Colon. Rectum.* – 1982. – Vol. 25. – P. 431-440.
4. Gillen, P. Comparison of the mortality, morbidity, and incidence of local recurrence in patients with rectal cancer treated by either stapled anterior resection or abdominoperineal resection / P. Gillen, A. L. Peel // *BJS.* – 1986. – Vol. 73. – P. 339-341.
5. Payne, J. E. Surgery for large bowel cancer in people aged 75 years and older / J. E. Payne, P. H. Chapuis, M. T. Pheils // *Dis. Colon. Rectum.* – 1986. – Vol. 29. – P. 733-737.
6. Kinn, A. C. Bladder and sexual function after surgery for rectal cancer / A. C. Kinn, U. Ohman // *Dis. Colon. Rectum.* – 1986. – Vol. 29. – P. 43-48.
7. Bladder and erectile dysfunction before and after rectal surgery for cancer / J. Leveckis [et al.] // *Br. J. Urol.* – 1995. – Vol. 76. – P. 752-756.
8. Hermanek, P. Early (microinvasive) colorectal carcinoma. Pathology, diagnosis, surgical treatment / P. Hermanek, F. P. Gall // *Colorectal Dis.* – 1986. – Vol. 1. – P. 79-84.
9. Lymph node metastases in early rectal cancer / S. P. Huddy [et al.] // *BJS.* – 1993. – Vol. 80. – P. 1457-1458.
10. Said, S. TEM-minimal invasive therapy of rectal cancer? / S. Said, J. M. Muller // *Swiss Surg.* – 1997. – Vol. 3. – P. 248-254.
11. Transanal endoscopic microsurgery – initial experience from three centres in the United Kingdom / R. J. C. Steele [et al.] // *BJS.* – 1996. – Vol. 83. – P. 207-210.
12. Is transanal endoscopic microsurgery (TEM) a valid treatment for rectal tumors? / E. Lezoche [et al.] // *Surg. Endosc.* – 1996. – Vol. 10. – P. 736-741.
13. Buess, G. F. Transanal endoscopic microsurgery (TEM) / G. F. Buess, B. Mentges // *Minimally Invasive Therapy.* – 1992. – Vol. 1. – P. 101-109.
14. Saclarides, T. J. Transanal endoscopic microsurgery: a single surgeon's experience / T. J. Saclarides // *Arch. Surg.* – 1998. – Vol. 133. – P. 595-599.
15. Pollard, S. G. Villous tumours of the large bowel / S. G. Pollard, R. Macfarlane, W. G. Everett // *BJS.* – 1988. – Vol. 75. – P. 910-912.
16. Sakamoto, G. D. Transanal excision of large, rectal villous adenomas / G. D. Sakamoto, J. M. MacKeigan, A. J. Senagore // *Dis. Colon. Rectum.* – 1991. – Vol. 34. – P. 880-885.
17. Buess, G. Transanal endoscopic microsurgery (TEM): Review / G. Buess // *J. R. Coll Surg. Edinb.* – 1993. – Vol. 38. – P. 239-245.
18. Technique and results of transanal endoscopic microsurgery in early rectal cancer / G. Buess [et al.] // *The Am. J. Surg.* – 1992. – Vol. 163. – P. 63-70.
19. Transanal endoscopic microsurgery – lessons from a single UK centre series / G. M. Lloyd [et al.] // *Colorectal Dis.* – 2002. – Vol. 4. – P. 467-472.
20. Transanal endoscopic microsurgery: initial registry results / L. E. Smith [et al.] // *Dis. Colon. Rectum.* – 1996. – Vol. 39. – P. S79-S84.

Адрес для корреспонденции

Valdemaras Jotautas,
Center of Abdominal Surgery,
Clinic of Gastroenterology and
Abdominal Surgery,
Vilnius University Hospital
«Santariskiu Klinikos», Santariskiu 2,
08406 Vilnius, Lithuania
e-mail: valdemaras.jotautas@santa.lt

Поступила 26.10.2009 г.