

THE ENDO-EXO-FEMORAL PROSTHESIS

H.-H. Aschoff

*Sana Kliniken Lübeck GmbH
Klinik für Plastische, Hand- und Rekonstruktive Chirurgie*

Patients with above knee amputation (AKA) face many challenges to mobility including difficulty with socket fit and fatigue due to high energy consumption. The aim of the Endo-Exo-Femur Prosthesis (EEFP) is to avoid problems at the interface between the sleeve of the socket-prosthesis and the soft tissue coat of the femur stump which often impedes an inconspicuous and harmonic gait. In 1999 we began using a transcutaneous, press-fit distal femoral intramedullary device whose most distal external aspect serves as a hard point for AKA prosthesis attachment. The bone guided prosthesis enables an advanced gait via osseoperception and leads to a decreased oxygen consumption of the patient. Thirty two patients underwent the procedure between 1999 and 2008. Their indication for surgery was persistent AKA prosthesis difficulties with a history of AKA for trauma. The paper presents the patient data regarding the design of the implant, the operative procedure, patient satisfaction, gait analysis and oxygen consumption.

Key words: above knee amputation, osseointegrated femoral prosthesis, rehabilitation.

БЕДРЕННЫЙ ЭНДО-ЭКЗОПРОТЕЗ

Пациенты после ампутации конечности, выполненной выше коленного сустава, сталкиваются с множеством трудностей при передвижении, включая сложности с подгонкой гильзы и утомляемостью из-за больших затрат энергии. Бедренный эндо-экзо-протез позволяет избежать проблем, возникающих на границе между гильзой и гнездом протеза с одной стороны и мягкими тканями культи с другой, что часто препятствует гармоничной походке. С 1999 г. авторы стали использовать чрескожный интрамедуллярный штифт, внешняя дистальная часть которого служит в качестве жесткой опоры для крепления протеза. Управляемый костью протез позволяет улучшить походку благодаря остеоперцепции и сократить потребление кислорода пациентом. С 1999 по 2008 г. протез был имплантирован 32 больным. Показанием к оперативному вмешательству послужили постоянные проблемы при использовании протезов после ампутаций выше коленного сустава вследствие травм. В статье дано описание имплантата, технологии оперативного вмешательства, анализ удовлетворенности пациентов, их походки и потребления ими кислорода.

Ключевые слова: ампутация верхней конечности, остеointегрированный протез, реабилитация.

Introduction

Poor socket fit is a common problem and can be exacerbated by minor weight changes, sweating and skin problems which leads to a limited comfort for patients with an AKA wearing a socket femur prosthesis. A transcutaneous intramedullary femoral prosthesis would be able to elude these disadvantages and allows a more direct transmission of muscle power to the lower leg prosthesis.

The configuration of a bone guided soft tissue perforating femoral prosthesis thereby has to fulfil two different but equivalent requirements. Firstly, there is a need of a secure and durable fixation of the shaft of the prosthesis within the femur and secondly a most reliable shielding of the endomodule against possible ascending infections arising from the penetration of the prosthesis [5]. Based on the fundamental research in tooth implantology by Albrektsson and Branemark [1, 2, 3] the term "Osseointegration" became popular in conjunction with cementless implanted prostheses.

The Endo-Exo Femoral Prosthesis (EEFP) is a cobalt-chrome alloy device covered with spongi-

osa metal which creates a deep porous surface and favorable modulus for bone formation. The use of spongiosa metal surface of the cementless prosthesis is warranting for secure osseointegration. The three dimensional surface allows the ingrowth of bone into the spongiosa like structure of the implant. The broken surface structure concede only very little movement between bone and implant which impedes the accruing of a connective tissue interface [8, 9]. The EEFP is implanted in retrograde fashion as a first stage, followed some weeks later by stomatization whereby the distal aspect of the implant is exposed and an extension added for fixation of the AKA prosthesis. The stoma matures and epithelializes while solid bony ingrowth inhibits ascending infection.

With the background of 30 years of clinical experience in cementless hip, knee and tumor prosthesis, an intramedullary femoral prosthesis made out of three main components has been developed:

1) the femoral implant itself with a spongiosa like surface (spongiosa metal) for a safe intramedullary anchoring via osseointegration;

2) the adjustable intermediate module with a smooth surface penetrating the soft tissue;

3) the exomodule to which the lower leg prosthesis can be connected.

The cone of the endo-module, as a transition from the bone-guided to the soft tissue – covered implant section has to be looked at as a locus minoris resistentiae. This zone is subjected to high mechanical demands, especially during changing loads. Therefore additionally the system contains a sleeve with a short anterior bracket, which optionally serves to protect the transition from the bone-guided section of the prosthesis to the soft tissue covered implant section against possible fatigue fracture (fig. 1, 2).



Fig. 1. Endo-Exo Femurprosthesis



Fig. 2. EEFP in detail

Clinical history. Suitable patients for EEFP care are recruited from above-knee amputated patients whose disability can be ascribed to a trauma or a tumor-related disease. The currently valid exclusion criteria:

- 1) Collateral diseases, such as:
 - diabetes mellitus
 - vascular diseases
 - psychiatric diseases;
- 2) long-term medication with
 - chemotherapeutics,
 - preparations containing cortisone;
- 3) pregnancy / lactation;
- 4) incomplete skeletal growth;
- 5) insufficient patient compliance;
- 6) legal incapacity;
- 7) residence in an asylum.

The EEFP was implanted for the first time in 1999 in Lübeck [7]. In total, 32 patients were outfitted with a EEFP in the period from 1999 to December 2008, 30 of these in our department. The majority of our patients underwent above-knee

amputation because of a traumatic genesis (only in 4 cases was the amputation due to the presence of a tumor), with a mixed pattern of collateral diseases and disabilities (tabl. 1).

Table 1

Patient data*	
Number of patients (men / women)	32 (28 : 4)
Mean age (at time of amputation)	32.6 (14–56)
Mean age (at time of implantation)	44.0 (17–69)
Side (right/ left / both)	15 / 17 / 1
Reason for amputation (trauma/tumor/other)	27 / 4 / 1

* of the 32 patients treated in our clinic.

Operative planning. The operative planning consists of the findings at the femoral stump including scars as well as determining the prospective length and diameter of the prosthesis. The implantation of an EEFP requires comprehensive preparations with plan sketches supported by x-ray images.

The implantation of the EEFP is a two step procedure. The first step is the implantation of the endo module into the femur (fig. 3) and closure of the soft tissue over the stump just to give the spongiosa of the femoral bone enough time to integrate into the spongiosa metal of the implant in terms of a biological protection against an uprising intramedullary infection. With the second step after six weeks the stoma will be performed using a special ring broach, afterwards the intermediate module can be connected (fig. 4, 5).

After labwise, radiologic and clinical control a part weight bearing of the prosthesis can be started after 1–3 weeks. Full weight bearing and secure gait can be achieved 2–6 weeks after the second step procedure (fig. 6, 7).

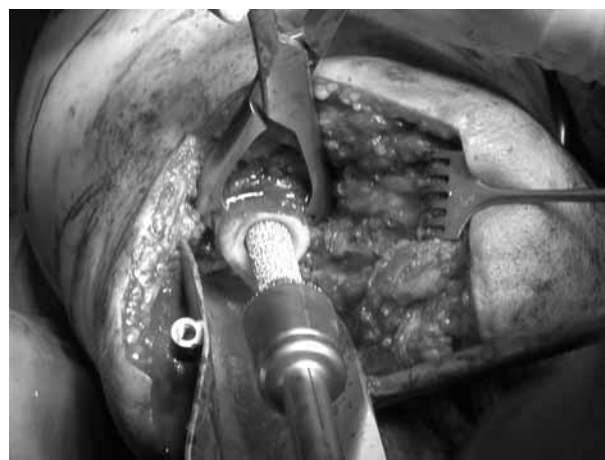


Fig. 3. Intramedullary Implantation of EEFP (first step)

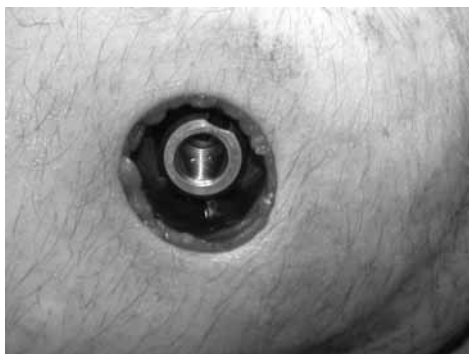

Fig. 4. Stomatization 6 weeks later (second step)



Fig. 5. Situation after adjusting the intermediate modul

Results

In total, 32 patients were outfitted with an EEFP in the period from 1999 to December 2008, of which 30 have been undergoing treatment since 2003 in our clinic.

In one case, in 2002, the prosthesis had to be removed at another hospital due to unconfirmed suspected post-operative intramedullary infection.

Another patient showed an ascending intramedullary infection 15 month after the first step operation so that ultimately the implant had to be removed 24 month after implantation.

In one case, seven years after implantation the prosthetic shank had to be replaced because of implant failure, with the patient in good condition to date.

Another explantation had to be done 24 month after implantation due to chronic soft tissue infection accompanied by an expanded necrosis of the ventral part of the corticalis at the distal femurstump. The femurstump had to be shortened and re-implantation then became possible after a delay of 10 month.

The remaining 28 patients are still outfitted with the original endo module.

Two peritrochanteric fractures of traumatic origin could be stabilized with the existing EEFP with the use of dynamic hip screws (DHS).

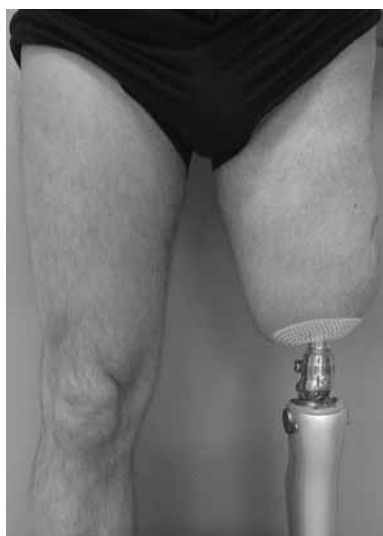

Fig. 6. EEFP connected to Exoprosthesis, full weight bearing 2 month after second step

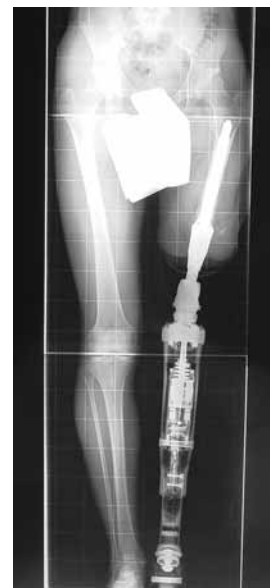

Fig. 7. X-ray of both legs – same patient as fig. 6

One of our patients was treated with distraction of the short femur stump before implantation of the EEFP. The left femur bone was distracted for 6 month with an extension of 10.5 cm. After consolidation of the distracted bone the EEFP was implanted 18 month after the beginning of the procedure. After another 6 month the patient reached full weight bearing and a secure gait (fig. 8–11).

We operated one patient with a traumatic bilateral above knee amputation where rehabilitation with socket prostheses was not successful. The EEFP procedure was uncomplicated and 4 month after the bilateral implantation the patient was able to walk again (fig. 12–15).

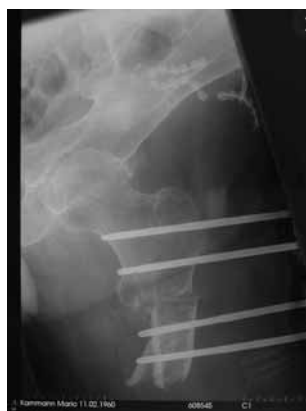

Fig. 8. Femur stump after corticotomie

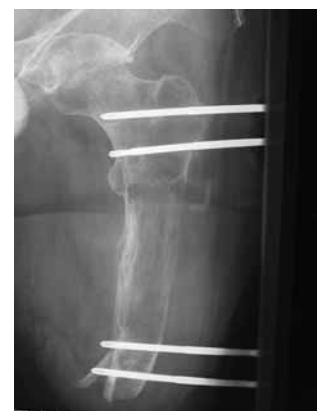

Fig. 9. Femur stump after distraction

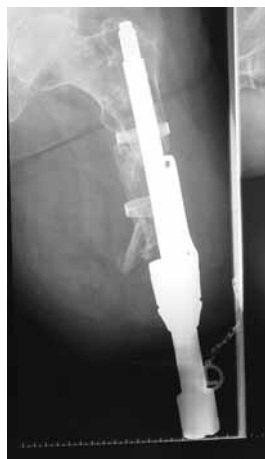


Fig. 10. Femur after implantation of EEFP



Fig. 11. Patient 2 years after beginning of procedure, full weight bearing

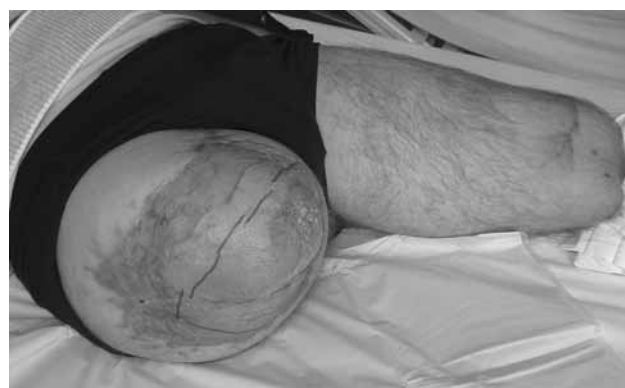

Fig. 12. Bilateral above knee amputation

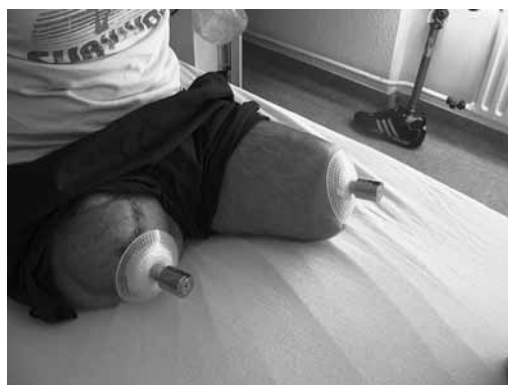

Fig. 13. Patient after bilateral implantation of EEFP

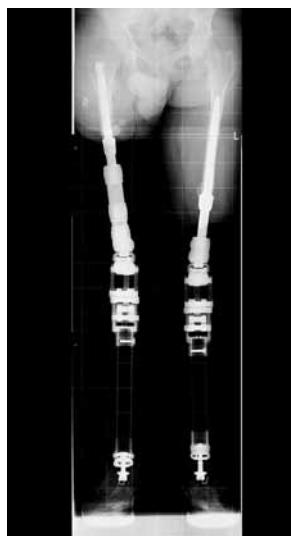


Fig. 14. X-ray of both legs — same patient as fig. 13

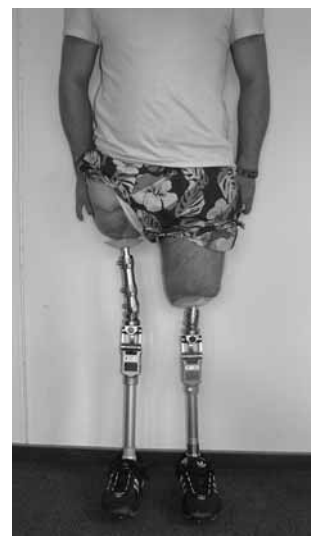

Fig. 15. Full weight bearing on both legs 3 month after EEFP

20 of a total of 32 patients that we treated suffered a chronic irritation of the soft tissues in the stoma region, in some cases making operative revisions necessary. Considerable narrowing and high-gloss polishing of the intermediary module enabled us to solve this border zone problem. Of the ten patients in our care since 2007, such operative revisions were thus no longer necessary.

With respect to the wearing comfort of the prosthesis, all patients found distinct advantages compared with prostheses surrounding the shaft. The degree of mobility was clearly improved and, in five cases, mobility without a wheelchair was possible only following implantation of the EEFP.

In retrospect, all patients operated would prefer care with an EEFP to that with a prosthesis surrounding the shaft.

The table 2 is giving a general overview about the patients having been treated with EEFP.

Table 2

32	Patients operated in total
1	Explantation due to intramedullary infection
1	Explantation due to chronic soft tissue problems
1	Explantation due to chronic soft tissue problems with reimplantation
1	Explantation due to failure of implant after 7 years with reimplantation
2	Patients with severe but controllable infections at the stoma
10	Patients with change of bracket due to soft tissue problems
2	Patients with pertrochanteric fractures of femur after EEFP
1	Patients with Distraction of the femurstump before implantation of EEFP
1	Patients with change from a tumorprosthesis to EEFP
1	Patients with bilateral EEFP after bilateral AKA
11	Patients with only minor or no problems at all

Gait analysis

According to a gait analysis lab-program established in 2007 patients with an EEFP are given a gait analysis before and after the implantation. This shows interesting data in terms of security and symmetric of the patient gait. Bone-guided femoral prostheses seem to raise the level of mobility in terms of walking speed and security of locomotion. Also there are expected hints for significant lower energy consumption for patients supplied with an EEFP compared to patients wearing a socket prosthesis. More exact investigations of these points are currently being conducted and will be concluded in the next future.

Summary

For the patients, the EEFP represents a significant improvement in terms of wearing comfort and stump situation. Such advantages as the significantly shorter time required for putting on, lack of dependence on already existing scars, changing body weight and the resulting modified stump form, the absence of skin irritations and pressure-related injuries due to the support of the prosthetic shank more than compensate for the slightly greater attention to the care of the soft tissue and stoma regions. Furthermore, patients report improved mobility as a result of less restriction of movement (above all when sitting), longer periods of endurance and improved sureness of walking compared with shaft prostheses. The last of these advantages can be explained on the basis of recovering osseo-perceptive capabilities due to the bone guidance of the prosthesis. All patients report an improvement in sense of position and tactile sensation following care with the EEFP, this in turn leads to an improved gait pattern. Comparable results were reported by the Branemark group [6] from Gothenburg/Sweden.

The situation in regard to infections in the stoma region can be seen as under control. An accumulation of germs in the stoma – predominantly germs originating in the natural skin flora – is regularly observed [4]. Since the introduction of high-gloss polished surfaces, infections requiring medical intervention in the soft tissue region are now the exception. The frequently discussed risk of intramedullary infections can, in consideration of the results to date, be seen as negligible. Due to the osseous integration of the prosthetic shank, already 2–3 weeks following the operation there is sufficient sealing off of the medullary cavity against ascending infections. This assertion is supported by the fact that with the first patients, whose history was

partly characterized by the spreading of soft tissue infections (in some cases with MRSA), no indications were observed for the loosening of the prosthesis or the presence of intramedullary infections.

In summary, in our opinion outfitting with the EEFP can be seen as a suitable procedure for the care of upper leg amputated patients. This is especially true for patients who have been only insufficiently cared for with prostheses surrounding the shaft. The development of a score for the support of these indications is planned.

In the future, the subject of extending care to other extremities, e.g. the upper arm and the crural region, will be of interest. Furthermore, on the basis of the positive results found to date, it might be worth exploring the potential for extending the group of indications to include patients with vascular disease, such as peripheral circulatory disturbances.

Literature

1. Albrektsson, T. Osseointegration of bone implants. A review of an alternative mode of fixation / T. Albrektsson, B. Albrektsson // *Acta Orthop. Scand.* — 1987. — Vol. 58, N 5. — P. 567–577.
2. Albrektsson, T. Present clinical applications of osseointegrated percutaneous implants / T. Albrektsson, P.I. Branemark, M. Jacobsson, A. Tjellström // *Plast. Reconstr. Surg.* — 1987. — Vol. 79, N 5. — P. 721–731.
3. Branemark, R. Osseointegration in skeletal reconstructions and rehabilitation: a review // R. Branemark, P.I. Branemark, B. Rydevik, R.R. Myers // *J. Rehab. Res. Dev.* — 2001. — Vol. 38, N 2. — P. 175–181.
4. Clausen, A. Die I.S.P.-Endo-Exo-Femurprothese, Anwendung und Verlaufsbeobachtung sowie Anpassung des Implantatdesigns unter Berücksichtigung der Erkenntnisse mikrobiologischer und histologischer Untersuchungen an der Grenzzone, Orthopädische Klinik und Poliklinik der Ludwigs-Maximilians-Universität : Dissertation. — München, 2008. — 61 s.
5. Grosse-Siestrup, C. Design criteria for percutaneous devices / C. Grosse-Siestrup, K. Affeld // *J. Biomed. Mat. Rest.* — 1984. — Vol. 18. — P. 357–382.
6. Osseoperception and osseointegrated prosthetic limbs / K. Hagberg [et al.] // *Psychoprosthetics* / P. Gallagher, D. Desmond, M. MacLachlan. — London, 2008. — P. 131–140.
7. Staubach, K.H. Die erste osteointegrierte perkutane Prothesenverankerung für Oberschenkelamputierte / K.H. Staubach, H. Grundei // *Biomed. Technik.* — 2001. — Bd. 46, H. 12. — S. 355–361.
8. Steinhauer, E. Biomechanische Grundlagen der Implantatverankerung // *Ossäre Integration* / R. Gradinger, H. Gollwitzer. — Heidelberg, 2006. — S. 17–23.
9. Vergleichendestatistische biomechanische Untersuchungen zu Tripoden, Oberflächenstrukturen zementfreier / W. Mittelmeier [et al.] // *Endoprothesen. Z. Orthop. Ihre Grenzgeb.* — 1999. — Bd. 137, H. 2. — P. 122–128.

СВЕДЕНИЯ ОБ АВТОРЕ:

Horst-Heinrich Aschoff – M.D., Head Doctor of Sana Kliniken, Lübeck GmbH, Department of Plastic, Hand- and Reconstructive Surgery
E-mail: h.aschoff@sana-luebeck.de