

# THE STUDY OF GLIOBLASTOMA DIFFERENTIATION POSSIBILITY

UDC 616–006.484–079.4

Received 20.02.2014

© **I.A. Medyanik**, PhD, Senior Research Worker<sup>1</sup>;  
**A.S. Gordetsov**, D.Chem.Sc., Professor, Head of the Department of General Chemistry<sup>2</sup>;  
**O.V. Krasnikova**, PhD, Assistant, the Department of General Chemistry<sup>2</sup>;  
**I.A. Lobanov**, Radiologist<sup>3</sup>;  
**V.V. Radovsky**, Pathologist<sup>4</sup>;  
**A.P. Fraerman**, D.Med.Sc., Professor, Chief Research Worker<sup>1</sup>;  
**I.G. Terentiev**, D.Med.Sc., Professor, Head of the Oncology Department, the Faculty of Doctors' Advanced Training<sup>2</sup>;  
**N.N. Karyakin**, PhD, Head of Research Institute<sup>1</sup>

<sup>1</sup>Nizhny Novgorod Research Institute of Traumatology and Orthopedics, Ministry of Health of the Russian Federation, Verkhne-Volzhskaya naberezhnaya St., 18, Nizhny Novgorod, Russian Federation, 603155;

<sup>2</sup>Nizhny Novgorod State Medical Academy, Minin and Pozharsky Square, 10/1, Nizhny Novgorod, Russian Federation, 603005;

<sup>3</sup>Diagnostic and Treatment Center of the International Institute of Biological Systems named after Dr. Sergey Berezin, Nesterova St., 34a, Nizhny Novgorod, Russian Federation, 603167;

<sup>4</sup>Nizhny Novgorod Regional Children's Teaching Hospital, Vaneeva St., 211, Nizhny Novgorod, Russian Federation, 603136

**The aim of the investigation** was to assess the possibility of glioblastoma differentiation using infrared spectroscopy, proton magnetic resonance spectroscopy and immunohistochemistry.

**Materials and Methods.** 22 patients with glioblastomas and 21 patients with anaplastic astrocytomas were examined. All the patients underwent infrared spectroscopy of blood serum. 16 patients with glioblastomas were examined preoperatively and postoperatively, and in both cases 7 of them underwent proton magnetic resonance spectroscopy of tumors and identical peritumoral areas. All diagnoses were morphologically confirmed, and 10 cases with glioblastomas and 15 cases with anaplastic astrocytomas were confirmed by immunohistochemistry.

**Results.** Glioblastoma differentiation (Grade IV) into anaplastic astrocytomas (Grade III) was revealed postoperatively, in total glioblastoma resection and confirmed by the findings of infrared spectroscopy in blood serum, proton magnetic resonance spectroscopy of identical peritumoral areas performed preoperatively and postoperatively, as well as by immunohistochemical investigation of peritumoral area.

**Conclusion.** The complex of the techniques applied (infrared spectroscopy, proton magnetic resonance spectroscopy, immunohistochemistry) enables to assess how effective and total the surgery was, and if it promoted glioblastoma differentiation postoperatively, and determine how the tumor will develop after the surgery: as glioblastoma — with early continuous tumor growth, or as anaplastic astrocytoma — with the longer recurrence-free period. The findings are in agreement with tissue theory of tumor genesis; and change the understanding of the role and significance of surgical resection of glioblastomas in tumor differentiation.

**Key words:** glioblastoma; glioblastoma differentiation; anaplastic astrocytoma; infrared spectroscopy.

Along with a regular course of a tumor process — gradual transformation in low-grade and undifferentiated tumors — the transformation of malignant tumors into ones with lower anaplasia degree is also possible — reverse transformation (differentiation, reversion). Experimental studies demonstrate the possibility of differentiation induction of glial tumor cells into mature glial cells and proliferation inhibition [1–4]. The authors describe various factors causing differentiation; however, the mechanism of the phenomenon is unclear [5].

There are a few reports in literature describing the differentiation of malignant brain tumors confirmed morphologically in surgical reinterventions [6, 7]. Glioblastoma is the most common malignant brain tumor. According to different authors, total survival rate

of patients with glioblastomas is 10–12 months, and patients with anaplastic astrocytic tumors — 20–24 months [8, 9].

A progression-free period, which can last from 1 to 12 months, is a significant criterion of efficiency assessment. A true cause of early or late continuous tumor growth is unknown. Total glioblastoma excision is considered to extend patients' life [10, 11].

Glial tumors are characterized by invasive growth extending in the surrounding marrow far beyond the main tumor node, and in 47% cases tumor cells are found in the opposite sphere [11, 12]. In general oncology and neuro-oncology infrared (IR) tissue spectroscopy is just the technique to detect tumor cells in the surrounding brain matter and determine tumor morphological

For contacts: Medyanik Igor Alexandrovich, phone +7 908-767-62-21; e-mail: med\_neuro@inbox.ru

character to high precision. The studies [13–17] show infrared spectra of tumor and non-tumor cells, grey and white matter, astrocytoma and glioblastoma tissues to differ from each other.

A tumor is pathological change of structural and functional condition of not only newly formed tissue, its microenvironment but also the whole body. All processes proceeding in the body, some systems and cell groups are known to affect blood serum. Glial tumor cells are known to produce certain substances causing the blood-brain barrier breakdown. As a result, under-oxidized products and waste products of tumor cells enter bloodstream [11, 18].

Our previous studies of blood serum using IR spectroscopy in patients with brain tumors revealed significant dependence between IR spectroscopy findings, morphological nature of tumors and tumor grade [19–21]. Based on these findings we examined the patients with glioblastomas preoperatively and postoperatively to determine if it is possible to reduce anaplasia degree of glioblastomas from Grade IV preoperatively to Grade III consistent with postoperative anaplastic astrocytomas, i.e. if there is differentiation of glioblastomas.

**The aim of the investigation** was to assess the possibility of glioblastoma differentiation using infrared spectroscopy, proton magnetic resonance spectroscopy and immunohistochemistry.

**Materials and Methods.** We carried out a single blind prospective cohort study of 43 patients with malignant brain tumors undergoing medical treatment in Nizhny Novgorod Interregional Neurosurgical Centre and Nizhny Novgorod Research Institute of Traumatology and Orthopedics, Ministry of Health of the Russian Federation, over the period 2009–2013. Glioblastomas (Grade IV) were diagnosed in 22 patients (51.16%), among them primary tumors (de novo) were detected in 21 patients, and one patient had secondary glioblastoma resulted from malignant transformation of excised anaplastic astrocytoma. Anaplastic astrocytomas (Grade III) were diagnosed in 21 patients (48.84%). Control group consisted of 28 healthy volunteers. All patients underwent blood serum IR-spectroscopy. Preoperative and postoperative IR-spectroscopy findings of 16 patients with glioblastomas were compared.

The study complies with the declaration of Helsinki (adopted in June, 1964 (Helsinki, Finland) and revised in October, 2000 (Edinburg, Scotland)), and was performed following approval by the ethic committee of Nizhny Novgorod Research Institute of Traumatology and Orthopedics. Written informed consent was obtained from all patients.

The research technique was as follows. 5.0 ml blood from cubital vein was centrifuged (1000 rpm) within 15 min. Separated serum (1.0 ml) was dried in a plate in a dry-air sterilizer at 25°C for 24 h. Dry residue was crushed and suspended in liquid paraffin. The research

was carried out on spectrophotometer Specord 75 IR (Carl Zeiss, Germany) in spectral range 1200–1000 cm<sup>-1</sup>. It enables to reveal full spectrum of substances in blood serum containing P–O and C–O bonds, ordinary bonds and ester groups C–OO, P–OO, all lipids, phosphorylated proteins, carbohydrates, creatine phosphokinase and other compounds referring to them. At first we determined peak height of absorption band with maxima 1170, 1165, 1160, 1150, 1140, 1130, 1125, 1100, 1070, 1050 and 1025 cm<sup>-1</sup>. To exclude errors in the assessment of IR-spectroscopy findings we studied not absolute values of peak height of absorption bands but calculated the ratio of peak height of absorption bands (cm<sup>-1</sup>/cm<sup>-1</sup>): 1 — 1165/1160, 2 — 1165/1070, 3 — 1165/1150, 4 — 1165/1140, 5 — 1040/1070, 6 — 1165/1130, 7 — 1070/1025, 8 — 1165/1050, 9 — 1165/1025, 10 — 1100/1050, 11 — 1170/1150, 12 — 1170/1160, 13 — 1125/1165. Fasting blood was withdrawn in the morning, before taking medicines, on the eve of the surgery (days 1–3), as well as postoperatively (days 3–10).

All histological diagnoses in a postoperative period were confirmed morphologically, and in 25 complicated cases (39.7%) — by immunohistochemistry (10 cases of glioblastomas, and 15 cases of anaplastic astrocytomas). We assessed the results of morphological studies using WHO classification [22]. The presence of two of four main malignant tumor criteria: nuclear polymorphism, mitoses, endothelial proliferation, necroses — is consistent with Grade III; the presence of at least three criteria corresponds to Grade IV [23].

Seven patients with glioblastomas underwent proton magnetic resonance spectroscopy (PMRS) of tumors and identical areas of perifocal zones preoperatively and postoperatively. MRI scanner Magnetom-Symphony 1.5 T (Siemens, Germany) with head coil was used. At first conventional brain examinations were performed with T2-, T1-weighted MR images in axial, sagittal and coronal planes, T2 Flair — in axial planes. Based on the obtained images we determined a region of interest for 2D-multi-voxel spectroscopy. After preset adjustment of MRI-scanner: shimming and suppression of water molecule proton signal we initiated protocol `csi_se 30` using Spectroscopy Evaluation. Further, after data post-processing we obtained graphic presentations of spectra parametric maps of metabolites and their ratios.

The findings were processed by univariate statistic techniques using Statistica 6.1. The results were presented as  $M \pm \sigma$ , where  $M$  — arithmetic mean,  $\sigma$  — standard deviation. Paired within-group and intergroup comparisons were performed using Student t-test, Wilcoxon and Mann–Whitney tests depending on the fulfillment of applied conditions. The samplings were considered to belong to different general populations if  $p \leq 0.05$ .

**Results.** To handle the problem of determining the diagnostic capability of different morphological types of tumors with different grades using IR-spectroscopy,

we first studied the ratio values of absorption band peaks depending on histological type of brain tumors in preoperative period (Table 1).

In the survey we revealed significant correlations between histological diagnoses confirmed by morphological (n=43) or immunohistochemical (n=25) studies, and ratio values of 13 absorption band peaks obtained by IR-spectroscopy of blood serum of the same patients.

In accordance with the findings, to have differential diagnostic profiles, we plotted diagrams consisting of 13 radial beams coming from the centre, with 30° angle between them. Each of the beams corresponds to a certain ratio of absorption bands. The obtained ratio

values were plotted on these beams, and the endpoints of the segments connected yielded plane polygons representing differential and diagnostic profiles of brain tumors (Fig. 1).

As a result of the examination of 22 patients with morphologically verified glioblastoma using IR-spectroscopy, we obtained certain repeated values of ratios common only to brain tumors — Grade IV glioblastomas (See Table 1, Fig. 1, a). The examination of 21 patients with postoperatively morphologically verified anaplastic astrocytoma gave certain repeated values of ratios typical of brain tumor — Grade III anaplastic astrocytoma (See Table 1, Fig. 1, b).

To identify the capabilities of glioblastoma

Table 1

The values of absorption IR spectrum band peak ratio of blood serum in patients with glioblastomas (Grade IV) and anaplastic astrocytomas (Grade III) in a preoperative period

| Beam number | Ratio of absorption bands, cm <sup>-1</sup> /cm <sup>-1</sup> | Norm (n=28) | Histological variant of tumor |                    |
|-------------|---|-------------|-------------------------------|--------------------|
|             |   |             | Glioblastoma (n=22)           | Astrocytoma (n=21) |
| 1           | 1165/1160   | 0.71±0.07   | 0.83±0.04*                    | 0.56±0.07**        |
| 2           | 1165/1070   | 0.82±0.21   | 1.16±0.12*                    | 0.54±0.06**        |
| 3           | 1165/1150   | 0.54±0.06   | 0.62±0.01*                    | 0.42±0.05**        |
| 4           | 1165/1140   | 0.50±0.08   | 0.63±0.04*                    | 0.39±0.02**        |
| 5           | 1040/1070   | 1.25±0.29   | 1.26±0.21                     | 1.34±0.16          |
| 6           | 1165/1130   | 0.84±0.26   | 1.26±0.13*                    | 0.73±0.17**        |
| 7           | 1070/1025   | 1.01±0.41   | 0.73±0.12                     | 0.72±0.12          |
| 8           | 1165/1050   | 0.64±0.18   | 0.96±0.13*                    | 0.44±0.01**        |
| 9           | 1165/1025   | 0.80±0.21   | 1.13±0.01*                    | 0.38±0.08**        |
| 10          | 1100/1050   | 0.28±0.17   | 0.27±0.13                     | 0.27±0.12          |
| 11          | 1170/1150   | 0.18±0.11   | 0.34±0.04*                    | 0.15±0.05**        |
| 12          | 1170/1160   | 0.24±0.14   | 0.34±0.14                     | 0.20±0.07          |
| 13          | 1125/1165   | 0.86±0.36   | 0.57±0.18                     | 0.97±0.17**        |

\* — significant differences with a group of healthy volunteers (p≤0.05); \* — with a group of patients with glioblastomas (p≤0.05).

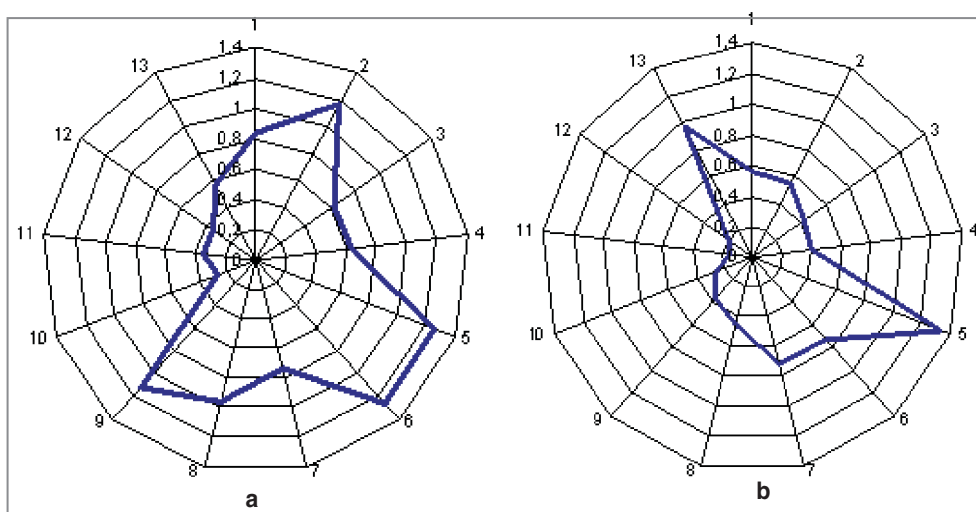


Fig. 1. Diagnostic profile based on averaged data: a — glioblastomas (Grade IV); b — astrocytomas (Grade III)

differentiation in a postoperative period using blood serum IR-spectroscopy we examined 16 patients with Grade IV glioblastoma and compared the findings with those of the same patients before the operation (Table 2).

It was found that in 12 cases of total tumor resection, in the postoperative period 13 values of absorption peak ratios and their diagrams changed and by their characteristics were consistent with the diagnosis “anaplastic astrocytoma” (Grade III). In four cases of subtotal tumor resection, postoperative IR-spectroscopy findings underwent no changes compared to preoperative findings and the diagnosis “glioblastoma” (Grade IV) remained. The volume of incised tumor was assessed by postoperative brain contrast CT and MRI. The absence of contrast accumulation in the operative intervention area was considered to be total tumor resection.

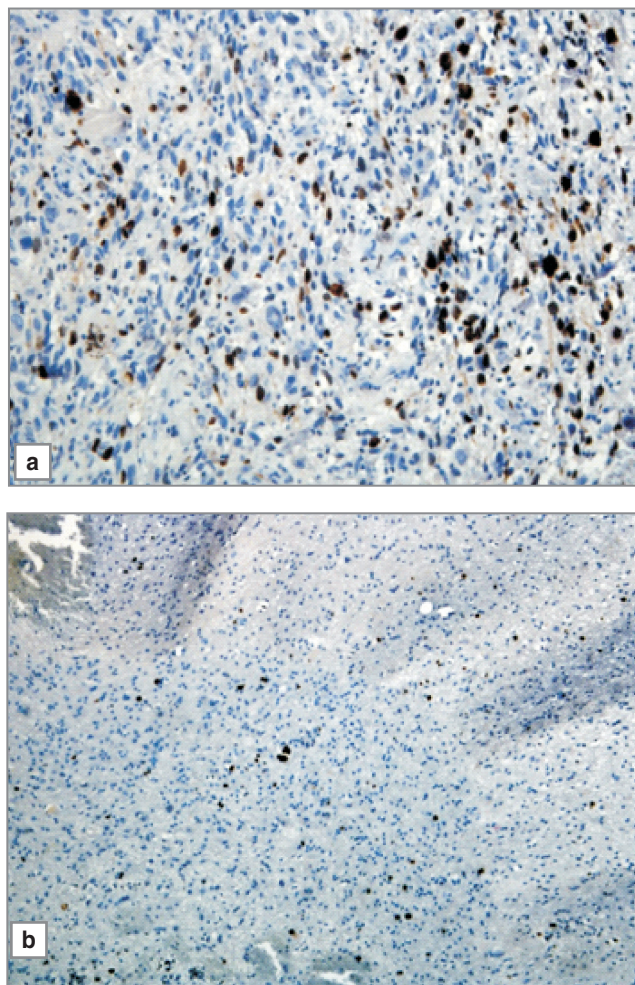
PMRS is known to enable to specify morphological tumor type, estimate anaplasia degree by the content and ratio values of metabolites in the tumor and peritumoral area [24–27].

Seven patients with glioblastomas underwent PMRS; we studied the tumor and peritumoral area condition preoperatively and postoperatively. Preoperative tumors of all patients were found to have significant increase of choline (Cho) peak height, significant decrease of NAA peak height and high double-peak of lactate (Lac). Choline/creatine (Cho/Cr) ratio was high (up to 20.1). There was also observed the significant increase of Lac/Cr ratio (up to 39). All the above mentioned data suggest high tumor grade — Grade IV. In the peritumoral area 1.0 cm away from a visible tumor edge there were observed moderate increase Cho peak height, insignificant decrease of NAA peak height and insignificant growth of Lac peak height.

Table 2

**Blood serum IR-spectroscopy findings of 16 patients with Grade IV glioblastomas based on the volume of incised tumor in a postoperative period**

| Absorption band ratio,<br>cm <sup>-1</sup> /cm <sup>-1</sup> | Resection volume |                |
|--|------------------|----------------|
|  | Total (n=12)     | Subtotal (n=4) |
| 1165/1160  | 0.56±0.07        | 0.83±0.04      |
| 1165/1070  | 0.54±0.06        | 1.16±0.12      |
| 1165/1150  | 0.42±0.05        | 0.62±0.01      |
| 1165/1140  | 0.39±0.02        | 0.63±0.04      |
| 1040/1070  | 1.34±0.16        | 1.26±0.21      |
| 1165/1130  | 0.73±0.17        | 1.26±0.13      |
| 1070/1025  | 0.72±0.12        | 0.73±0.12      |
| 1165/1050  | 0.44±0.01        | 0.96±0.13      |
| 1165/1025  | 0.38±0.08        | 1.13±0.01      |
| 1100/1050  | 0.27±0.12        | 0.27±0.13      |
| 1170/1150  | 0.15±0.05        | 0.34±0.04      |
| 1170/1160  | 0.20±0.07        | 0.34±0.14      |
| 1125/1165  | 0.97±0.17        | 0.57±0.18      |



**Fig. 2.** Ki-67 expression in nuclei of tumor cells: a — the main node of glioblastoma: 25%; ×200; b — peritumoral area: 10%; ×100

We found marked decrease of myoinositol/creatinine ratio (Ins/Cr) — 0.15±0.12, the increase of glutamine–glutamate/creatinine ratio (Glx/Cr) — 0.36±0.04. Cho/Cr ratio values in different voxels were 1.36±0.70. The obtained results were also consistent with Grade IV anaplasia. In all cases the diagnosis “glioblastoma” was confirmed by histological studies of different tumor parts. No heterogeneous tumors with different histological structure in one tumor node were found in our survey.

The same 7 patients after surgical resection of glioblastomas underwent PMRS of identical peritumoral areas. The comparative analysis of metabolic changes before and after tumor resection showed that postoperatively in the peritumoral area there was the reduction of Cho peak height, insignificant increase of Ins/Cr ratio values (0.22±0.29), the decrease of Glx/Cr ratio values (0.21±0.08), and the decreased Cho/Cr ratio values up to 0.69±0.23 indicating the reduced anaplasia degree up to Grade III–II.

The analysis of a proliferative activity marker Ki-67 in a solid part of the tumor and tumor cells of perifocal area

in 10 patients with glioblastomas after surgery showed proliferation index Ki-67 in the tumor to be on average 15–25% that is consistent with Grade IV glioblastoma (Fig. 2, a). In all cases we studied different tumor areas. There were revealed no mixed histological tumor types. The study of peritumoral areas of totally removed tumors, where tumor cells were found, Ki-67 averaged to 5–10% corresponding to Grade III–II tumors (Fig. 2, b) [22].

Below a clinical example is given.

*Patient S. was operated on for continuous tumor growth in the right temporal lobe 23.09.2013. Pathology report dated 01.10 — glioblastoma.*

*The patient underwent preoperative MRI (Fig. 3) and PMRS (Fig. 4, a), and in a postoperative period: a follow-up MRI (Fig. 5) and PMRS (Fig. 4, b).*

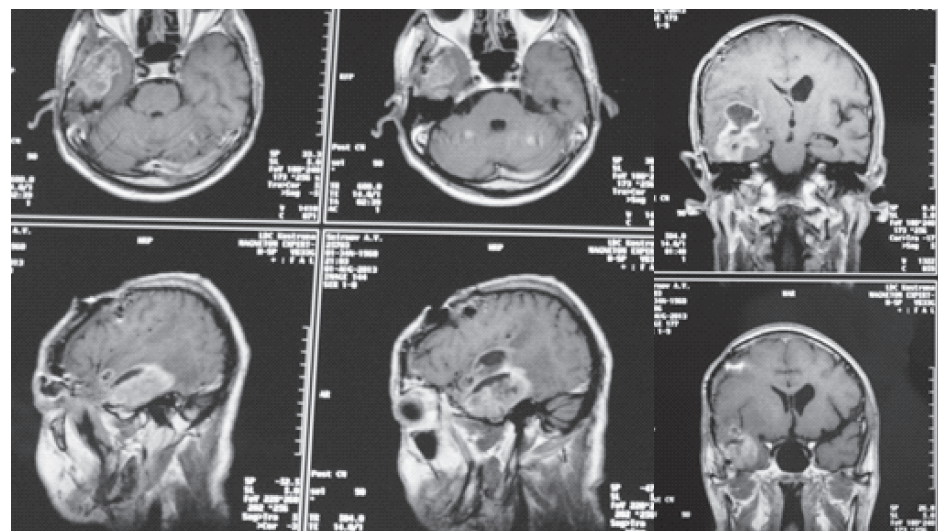
In a postoperative period 20 of 21 compared voxels (95.2%) have decreased value of Cho/Cr ratio ( $p < 0.01$ , Mann–Whitney criterion).

In four cases of subtotal tumor resection, preoperative

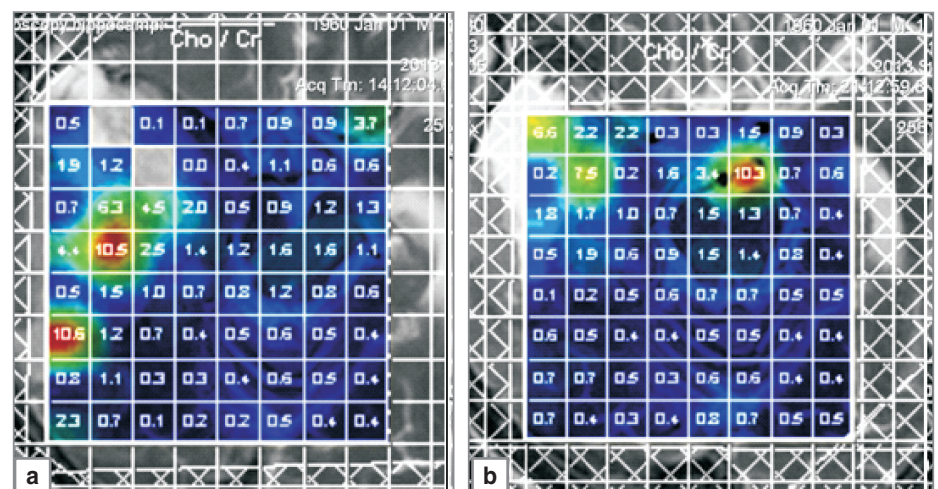
and postoperative blood serum IR-spectroscopy findings underwent no changes and corresponded to “glioblastoma” diagnosis. The comparison of PMRS findings of identical parts of the peritumoral area in preoperative and postoperative periods revealed that in some parts of the peritumoral area after subtotal tumor resection there was an insignificant decrease of Cho/Cr, Cho/NAA, Glx/Cr ratio values, and insignificant increase of NAA/Cr and Ins/Cr ratio values that indicates the reduced tumor grade, however, to a lesser degree compared to the total tumor resection. In adjacent peritumoral zones there were metabolic changes consistent with Grade IV that were not found in total tumor resection.

All four cases of subtotal tumor resection, morphological and immunohistochemical studies in peritumoral area revealed tumor cells of glioblastoma with high Ki-67 consistent with Grade IV.

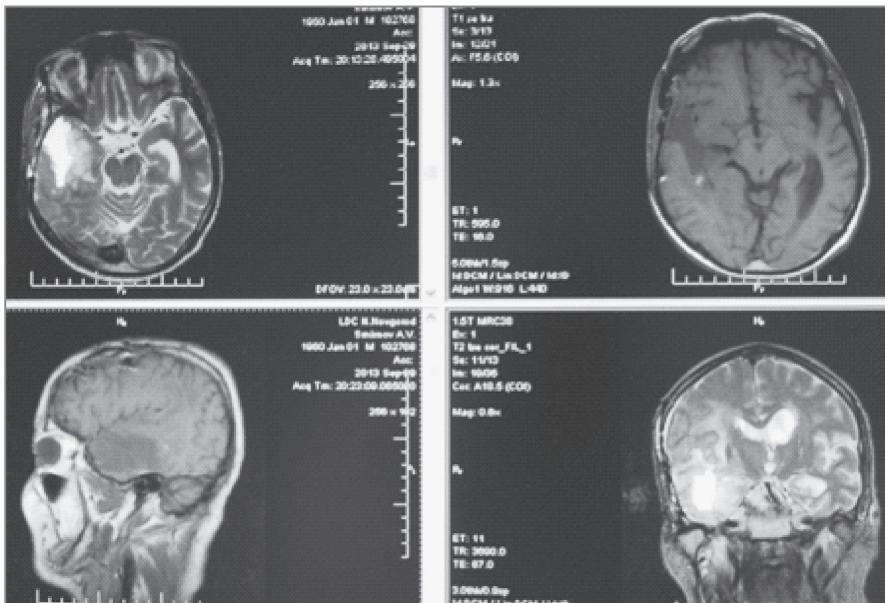
In all four cases of subtotal tumor resection there was observed an early (up to a month) continuous tumor growth.



**Fig. 3.** Contrast MRI of patient S. dated 01.08.2013. Continuous growth of cystic tumor of the right temporal lobe



**Fig. 4.** Patient S., 2D-multi-voxel PMRS. Color parametric maps. Cho/Cr ratio: a — preoperative MRS dated 17.09.2013; b — postoperative MRS dated 29.09.2013



**Fig. 5.** Patient S., contrast MRI dated 29.09.2013. The condition after the right temporal lobe tumor resection. The postoperative cyst edema. No contrast accumulation

**Discussion.** The obtained results of postoperative differentiation of glioblastoma (Grade IV) in anaplastic astrocytoma (Grade III) can be explained theoretically from the point of view of tissue oncogenesis theory, according to which a self-regulating system (homeostasis) controls the constancy of qualitative and quantitative composition of cells, which have the potency to independent growth. In accordance with this theory, tissue control abnormality results in uncontrolled division of clonogenic tumor stem cells having activated oncogenes [28]. This theory is sustained by the experiment of human glioblastoma stem cell transplanted in caudal nucleus of genetically modified nude thymic mouse brain. Histological type of tumors detected 10–19 days later in both cerebral hemispheres, and anaplasia degree depended on tumor site (microenvironment). So, in caudal nucleus or in adjacent parenchyma, tumor structure resembled human glioblastoma multiforme. Its subependymal layer looked like ependymastrocytoma, in choroid plexus the tumor had histological signs of choroid plexus carcinoma [29]. The effect of microenvironment on morphological differentiation of cells was confirmed by other researchers as well [30–32]. In oncodifferentiation processes the critical part is assigned to cell molecular and metabolic microenvironment of tumor cells including the relationship between tumor and non-tumor cells, stromal component factors, neuronal stem cells, tumor stem cells, as well as oxygen tension, acidity, lactate and glucose content, energy deficiency, interstitial fluid flow, interstitial hypertension, different factors produced by microenvironment cells, the factors having an effect on proliferation, cell division and differentiation [28, 33–35].

In total resection of a tumor node, at a single step there were removed the bulk of actively proliferating

tumor cells, the majority of chemo- and radioresistant tumor cells, tumor stem cells located in tumor stroma, necrotic foci, most tumor neovasculature, growth factors produced by tumor cells, cytokines, inflammatory mediators, antibodies, proteases and other enzyme types, different metabolites, and other indices. Postoperative blood flow, vascular permeability, acidity, osmotic and oncotic pressure, oxygen partial tension, etc. change significantly in peritumoral area. All the above mentioned significantly changes homeostasis of surrounding tissues. The residual tumor cells in the postoperative peritumoral zone are in the changed microenvironmental conditions. Microenvironmental homeostatic changes after the resection of the main tumor node if there is no mass effect of the tumor theoretically can contribute to the differentiation of glioblastoma (Grade IV) into less malignant brain tumor — anaplastic astrocytoma (Grade III).

The collected empirical and experimental data show genetic abnormalities to not always result in malignant transformation and active tumor growth. The results we obtained demonstrate that in case of total glioblastoma resection the postoperative diagnosis “glioblastoma” is not consistent with reality relying on the changes in the perifocal area that is supported by the findings of three different research techniques: IR-spectroscopy, PMRS, immunohistochemistry. Preoperative spectral ratio studied by IR-spectroscopy of blood serum correspond to Grade IV tumors, postoperative — Grade III tumors. According to PMRS findings compared with the identical peritumoral areas before and after surgery there is a reduced level of tumor metabolites and their ratios that indicates the decrease of anaplasia degree to Grade III in the postoperative period. Immunohistochemical analysis of proliferative activity of tumor cells by Ki-67 expression in a tumor node determines anaplasia degree: Grade

IV that is consistent with glioblastoma diagnosis. In peritumoral zone the index decreases up to Grade III–II compared to the main part of the tumor that corresponds to the diagnosis of anaplastic astrocytoma.

**Conclusion.** A complex of techniques applied (IR-spectroscopy, proton and magnetic resonance spectroscopy and immunohistochemistry) enables to assess how effective and total the surgery was, and if it contributed to postoperative glioblastoma differentiation, and estimate how the tumor will develop in an early postoperative period: as glioblastoma — with early continuous growth or as anaplastic astrocytoma — with the longer recurrence-free period.

Total resection of glial brain tumors is impossible due to their infiltrative growth character. However, surgery is still the principal component of malignant brain tumor treatment. Our studies show that total tumor resection is required to prevent early continuous tumor growth. Differentiation of Grade IV glioblastomas into Grade III anaplastic astrocytomas is accompanied by an increased progression-free period.

The revealed regularity enables to understand the mechanisms of malignant transformation and brain tumor differentiation, and offers the prospects of possible development of a target effect of the process.

**Study Finding.** The research was supported using extra-budgetary funds of Nizhny Novgorod State Medical Academy and Nizhny Novgorod Research Institute of Traumatology and Orthopedics.

**Conflict of Interests.** The authors have no conflict of interests to declare.

## References

1. Terés S., Lladó V., Higuera M., et al. 2-Hydroxyoleate, a nontoxic membrane binding anticancer drug, induces glioma cell differentiation and autophagy. *Proc Natl Acad Sci USA* 2012; 109(22): 8489–8494.
2. Xie Y.K., Huo S.F., Zhang G., et al. CDA-2 induces cell differentiation through suppressing Twist/SLUG signaling via miR-124 in glioma. *J Neurooncol* 2012; 110(2): 179–186, <http://dx.doi.org/10.1007/s11060-012-0961-x>.
3. Zhuang W., Long L., Zheng B., et al. Curcumin promotes differentiation of glioma-initiating cells by inducing autophagy. *Cancer Sci* 2012; 103(4): 684–690, <http://dx.doi.org/10.1111/j.1349-7006.2011.02198.x>.
4. Sukhdeo K., Hambardzumyan D., Rich J.N. Glioma development: where did it all go wrong? *Cell* 2011; 146(2): 187–188, <http://dx.doi.org/10.1016/j.cell.2011.06.047>.
5. Anisimov A.G., Volkova T.O., Chekmasova A.A., Nemova N.N. Chemically induced differentiation of tumor line cells. *Ontogenez* 2002; 33(5): 325–341.
6. Prityko A.G., Korshunov A.G., Kholodov B.V., et al. Transformatsiya medulloblastom u detey na fone polikhimioterapii s obrazovaniem astrotsitarnoy gliomy. V kn.: *Materialy III s'ezda neyrokhirurgov Rossii, 4–8 iyunya 2002 g., Sankt-Peterburg* [Medulloblastoma transformation in children with poly-chemotherapy with the formation of astrocytic glioma. In: Proceedings of III Russian Neurosurgery congress, June 4–8, 2002. Saint-Petersburg]. Saint Petersburg; 2002; p. 585–586.
7. Yang M.M., Singhal A., Rassekh S.R., et al. Possible differentiation of cerebral glioblastoma into pleomorphic xanthoastrocytoma: an unusual case in an infant. *J Neurosurg Pediatr* 2012; 9(5): 517–523, <http://dx.doi.org/10.3171/2012.1.PEDS11326>.
8. Olyushin V.E., Filatov M.V., Ostreyko O.V., et al. Kompleksnaya terapiya bol'nykh gliomami polushariy bol'shogo mozga: itogi poslednego desyatiletia i perspektivy. Kombinirovannoe lechenie opukholy golovnogo mozga. V kn.: *Materialy Vseros. konf., 17–19 maya 2004* [Complex therapy of patients with cerebral gliomas: the results of the last decade and prospective. Combined treatment of cerebral tumors. In: Proceedings of All-Russian conference, May 17–19, 2004]. Ekaterinburg; 2004; p. 72–73.
9. Kobayakov G.L. *Khimioterapiya v kompleksnom lechenii bol'nykh s pervichnymi zlokachestvennymi opukholyami golovnogo mozga*. Avtoref. dis. ... dok. med. nauk [Chemotherapy in complex therapy of patients with primary cerebral malignancies. Abstract of a thesis for the degree of Doctor of Medical Science]. Moscow; 2011.
10. Keles G.E., Anderson B., Berger M.S. The effect of extent of resection on time to tumor progression and survival in patients with glioblastoma multiforme of the cerebral hemisphere. *Surg Neurol* 1999; 52(4): 371–379.
11. Zozulya Yu.A. *Gliomy golovnogo mozga* [Cerebral gliomas]. Kiev: UIPK "EksOb"; 2007; 632 p.
12. Burger P.C., Dubois P.J., Schold S.C., et al. Computerized tomographic and pathologic studies of the untreated, quiescent, and recurrent glioblastoma multiforme. *J Neurosurg* 1983; 58(2): 159–169.
13. Tolstorozhev G.B., Skornyakov I.V., Butra I.V. Diagnosis of oncological human pathologies using infrared spectroscopy. *Zhurnal prikladnoy spektroskopii* 2009; 76(6): 805–816.
14. Stelling A.L., Toher D., Uckermann O., et al. Infrared spectroscopic studies of cells and tissues: triple helix proteins as a potential biomarker for tumors. *PLoS One* 2013; 8(3): e58332, <http://dx.doi.org/10.1371/journal.pone.0058332>.
15. Steiner G., Shaw A., Choo-Smith L.P., et al. Distinguishing and grading human gliomas by IR spectroscopy. *Biopolymers* 2003; 72(6): 464–471.
16. Krafft C., Sobottka S.B., Schackert G., Salzer R. Analysis of human brain tissue, brain tumors and tumor cells by infrared spectroscopic mapping. *Analyst* 2004; 129(10): 921–925, <http://dx.doi.org/10.1039/B408934K>.
17. Krafft C., Sobottka S.B., Geiger K.D., et al. Classification of malignant gliomas by infrared spectroscopic imaging and linear discriminant analysis. *Anal Bioanal Chem* 2007; 387(5): 1669–1677.
18. Ulitin A.Yu., Olyushin V.E., Safarov B.I., Matsko D.E. *Metastaticheskie opukholy golovnogo mozga* [Metastatic cerebral tumors]. Saint Petersburg: FGU «RNKhI im. prof. A.L. Polenova Rostekhnologii»; 2010; 381 p.
19. Gordetsov A.S., Medyanik I.A., Lebedev A.V., et al. *Sposob diagnostiki novoobrazovaniy golovnogo mozga* [Diagnostic technique of cerebral neoplasms]. Patent RF No. 2350953. 2009.
20. Gordetsov A.S. Infrakrasnaya spektroskopiya biologicheskikh zhidkostey i tkaney [Infrared spectroscopy of biological fluids and tissues]. *Sovremennye tekhnologii v medicine* 2010; 1: 84–98.
21. Gordetsov A.S., Medyanik I.A., Lebedev A.V., et al. Sposob differentsial'noy diagnostiki novoobrazovaniy golovnogo mozga. Polozhitel'noe reshenie o vydache patenta

RF ot 10.01.2014 g. po zayavke №2013101333 ot 10.01.2013 g. [Differential diagnostic technique of cerebral tumors. Russian Federation patent approval dated 10.01.2014, Application for a patent No.2013101333 dated 10.01.2013].

**22.** WHO *Classification of tumors, of the central nervous system*. Lion; 2007.

**23.** Daumas-Duport C. Histological grading of gliomas. *Curr Opin Neurol Neurosurg* 1992; 5: 924–931.

**24.** *Sovremennye tekhnologii i klinicheskie issledovaniya v neyrokhirurgii*. Tom I [Modern technologies and clinical studies in neurosurgery. Volume I]. Pod red. A.N. Konovalova [A.N. Konovalov, editor]. Moscow; 2012; 320 p.

**25.** Trufanov G.E., Tyutin L.A. *Magnitno-rezonansnaya spektroskopiya* [Magnetic resonance spectroscopy]. Saint Petersburg: ELBI–SPb; 2008; 239 p.

**26.** Kim J.H., Chang K.H., Na D.G., et al. 3T 1H-MR Spectroscopy in grading of cerebral gliomas: comparison of short and intermediate echo time sequences. *Am J Neuroradiol* 2006; 27(7): 1412–1418.

**27.** Karatağ O., Karatağ G.Y., Uysal E., et al. Can magnetic resonance spectroscopy adequately differentiate neoplastic from non-neoplastic and low-grade from high-grade lesions in brain masses? *Marmara Med Journal* 2010; 23(3): 326–338.

**28.** Cherezov A.E. *Obshchaya teoriya raka: tkanevyi*

*podkhod* [General tumor theory: tissue approach]. Moscow: Izd-vo MGU; 1997; 252 p.

**29.** Dong Y., Zhang G., Huang G., et al. Glioma stem cells involved in tumor tissue remodeling in a xenograft model. *J Neurosurg* 2010; 113(2): 249–260, <http://dx.doi.org/10.3171/2010.2.JNS09335>.

**30.** Borisov K.E., Makeeva D.D. Stem cells of cerebral gliomas. *Arkhiv patologii* 2013; 2: 43–52.

**31.** Talayev V.Yu., Matveichev A.V., Lomunova M.A., et al. The effect of human placenta cytotrophoblast cells on the maturation and T cell stimulating ability of dendritic cells in vitro. *Clin Experim Immunol* 2010; 162(1): 91–99.

**32.** Persano L., Rampazzo E., Basso G., Viola G. Glioblastoma cancer stem cells: role of the microenvironment and therapeutic targeting. *Biochem Pharmacol* 2012; 85(5): 612–622.

**33.** Berezhnaya N.M. The role of immune system cells in tumor microenvironment. II. Interaction of immune system cells with other components of microenvironment. *Onkologiya* 2009; 11(2): 86–93.

**34.** Osinskiy S.P., Vaupel' P. *Mikrofiziologiya* [Microphysiology]. Kiev: Naukova dumka; 2009; 254 p.

**35.** Lisyanyy N.I. Stem cells of malignant gliomas and their interaction with tissue cell microenvironment. *Ukr neyrokhirurgich zhurn* 2011; 2: 9–13.