

UDC 616.36 – 002.17 – 078: 57.083.3

*Zhuravlyova A.K.,
Ogneva E.V.,
Zhuravlyova L.V.*

**APPROACH TO DIAGNOSIS
OF LIVER FIBROSIS:
SERUM MARKERS REVIEW**

Zhuravleva Anna Konstantinovna, *PhD in Medicine, Assistant Lecturer*

Department of Internal Medicine № 3, Kharkiv National Medical University
4 Lenina Ave., Kharkiv, 61022, Ukraine

Ogneva Elena Valentinovna, *PhD in Medicine, Assistant Lecturer*

Department of Internal Medicine № 3, Kharkiv National Medical University
4 Lenina Ave., Kharkiv, 61022, Ukraine

Zhuravlyova Larysa Volodymirivna, *MD, Professor, Head of Department of Internal Medicine №3*
Kharkiv National Medical University, 4 Lenina Ave., Kharkiv, 61022, Ukraine; *E-mail: l.zhuravlyova@mail.ru*

АБСТРАКТ

Непатический фиброз является конечной стадией многих заболеваний печени. Изначально, гепатический фиброз считался необратимым, однако, гепатический фиброз теперь известен как динамический процесс с значительным потенциалом для разрешения. Своевременная диагностика фиброза печени может предотвратить развитие нежелательных осложнений. Традиционно диагностика и количественное определение фиброзированной ткани основывались на биопсии печени. Но у пункционной биопсии существует целый ряд недостатков, ограничивающих проведение этой процедуры. В данной статье рассматриваются современные методы оценки фиброза печени, основанные на определении сывороточных маркеров.

Ключевые слова: фиброз печени; сывороточные маркеры.

*Журавлёва А.К.,
Огнева Е.В.,
Журавлёва Л.В.*

**ПОДХОД К ДИАГНОСТИКЕ
ФИБРОЗА ПЕЧЕНИ:
СЫВОРОТОЧНЫЕ МАРКЕРЫ**

Журавлёва Анна Константиновна,

к.м.н, ассистент кафедры внутренней медицины №3

Харьковский национальный медицинский университет, кафедра внутренней медицины № 3,
пр.-т Ленина 4, г. Харьков, 61022, Украина; *E-mail: vnmed3@gmail.com*

Огнева Елена Валентиновна, *к.м.н, ассистент кафедры внутренней медицины №3*

Харьковский национальный медицинский университет, кафедра внутренней медицины № 3,
проспект Ленина 4, г. Харьков, 61022, Украина

Журавлева Лариса Владимировна, *доктор медицинских наук, профессор, заведующая кафедрой внутренней медицины №3 Харьковского национального медицинского Университета*
кафедра внутренней медицины №3; пр.-т Ленина 4, г. Харьков, 61022, Украина; *E-mail: l.zhuravlyova@mail.ru*

АННОТАЦИЯ

Фиброз печеночной ткани является завершающей стадией развития различных заболеваний печени. Первоначально считалось, что фиброз необратим, но в настоящее время уже известно, что это динамический процесс, имеющий значительный потенциал для обратного развития. Своевременная диагностика фиброза печени может предотвратить возникновение нежелательных осложнений. Традиционно диагностика и количественное определение фиброзированной ткани основывались на биопсии печени. Но у пункционной биопсии существует целый ряд недостатков, ограничивающих проведение этой процедуры. В данной статье рассматриваются современные методы оценки фиброза печени, основанные на определении сывороточных маркеров.

Ключевые слова: фиброз печени, сывороточные маркеры.

Hepatic fibrosis is the final stage of many disorders of the liver. Originally, hepatic fibrosis was considered irreversible, however, hepatic fibrosis is now known to be a dynamic process with a significant potential for resolution. The diagnosis of chronic diffuse liver diseases, especially in the early stages of the development of histological changes is a rather complex problem. Early diagnosis of liver fibrosis is very important, since the initial stages of fibrosis are reversible and timely initiation of treatment will help prevent further progression of the process and the development of unwanted complications.

Hepatic fibrosis occurs in response to almost all causes of chronic liver injury. Hepatic fibrosis can occur in response to viral, immune, and toxic-metabolic insults and consists of an accumulation of fibrillar extracellular matrix (ECM) components. This process may ultimately lead to cirrhosis with its consequences of portal hypertension, hepatocellular carcinoma, and liver failure [1]. There is a relationship between the value of liver stiffness and various complications of cirrhosis, such as esophageal varices, variceal bleeding, portal hypertension, ascites, and hepatocellular carcinoma [2]. Significant discoveries into the mechanisms of hepatic fibrosis progression and regression have uncovered a number of potential targets for antifibrotic drugs.

The gold standard for the diagnosis of histological changes of the liver is a liver biopsy. However, its widespread use in practice is limited since it does not satisfy quality criteria as a surrogate end-point marker because of its complication rate, sampling error, intra- and interobserver variability, expense, and patient reluctance to undergo serial monitoring. But with drugs that have the potential to reverse hepatic fibrosis imminent, a simple, noninvasive, reproducible method of assessing fibrosis is essential to monitor disease progression, clinical outcomes, and response to treatment [3]. This was the basis for the introduction into clinical practice of noninvasive diagnosis of liver fibrosis.

Our deeper understanding of the mechanisms of fibrosis has led to the identification of many potential markers of fibrosis, which appear capable of identifying early and advanced hepatic fibrosis. Standard cross-sectional imaging studies will only identify or exclude advanced fibrosis [4]. Novel technologies such as transient hepatic

elastography and magnetic resonance imaging (MRI) elastography show promise as noninvasive methods of testing for hepatic fibrosis but they have small value in identifying early stages of fibrosis and low-grade inflammation. There is also a significant degree of subjectivity in the pathologic assessment of liver biopsy samples. A number of staging systems have been developed to reduce both the interobserver and intraobserver variability, including the METAVIR, the Knodell fibrosis score (later modified by Ishak), and the Scheuer score. Most studies have shown excellent inter- and intraobserver reproducibility for the staging of fibrosis. However, the reproducibility of hepatic inflammatory activity is not as consistent [1].

A large number of putative serum markers have been evaluated for the assessment of hepatic fibrosis. Despite the dynamic nature of hepatic fibrogenesis, most of the presumed tests are suitable for the cross-sectional diagnosis of fibrosis stage rather than determining the rate of fibrosis progression or regression. No true serum marker that would act as a surrogate marker of hepatic fibrosis has been validated to date. It is almost certain that combinations of biomarkers will probably have to be examined [2].

Broadly speaking, serum markers of hepatic fibrosis can be considered in 1 of 2 categories: either indirect or direct. Indirect markers reflect alterations in hepatic function but do not directly reflect hepatic ECM metabolism, for example, platelet count, coagulation studies, and hepatic aminotransferases. Direct serum assays for markers of fibrosis reflect serum ECM turnover. The discovery of many of these direct biomarkers is directly attributable to advances in the understanding of the molecular mechanisms involved in hepatic fibrogenesis. Serum assays for enzymes and products of matrix synthesis or degradation have been evaluated as markers of fibrosis in many studies and show some promise as a simple alternative to liver biopsy [3].

From indirect markers serum alaninaminotransferase (ALT) levels indicate liver inflammation, and high inflammatory activity is always accompanied by fibrogenesis. That is why high levels of ALT in serum are considered to have high rates of specificity and sensitivity on histological features of inflammatory activity and liver fibrosis. It was established that the increase of ALT

more than 2.5 times of the normal range reflects histological changes corresponding to A1-F1 in 28% of patients, while at the same time 26% of patients with the same histological features A1-F1 have normal ALT levels. The level of aspartat-aminotransferase (AST) has stronger correlation with fibrosis than ALT. Thus ratio $AST/ALT > 1$ is a likely indicator of severe stages of fibrosis and cirrhosis. Ratio $AST/ALT > 1.16$ with sensitivity of 81.3% and a specificity of 55.3% predicts the presence of cirrhosis. Combination of AST/ALT ratio with platelet levels contributes to its diagnostic value as it is known that thrombocytopenia is a marker of liver cirrhosis [2, 5, 6].

Advancing liver fibrosis is associated with reduced thrombopoietin production and increased platelet sequestration in the spleen and also with reduced clearance of AST. The AST to platelet ratio index (APRI) is easy available simple index and is calculated as follows: $APRI = (AST/\text{upper limit of normal}) \times 100/\text{platelet count}$. A recent meta-analysis of 22 studies, predominantly involving chronic HCV patients, made a number of observations. At an APRI threshold of 0.5, the sensitivity and specificity for significant fibrosis were 81% and 50%, respectively. At an APRI threshold of 1, the sensitivity and specificity for predicting cirrhosis were 76% and 71%, respectively [1, 6, 7].

Direct markers of liver fibrosis include a number of serum or urinary markers, which have been shown to be or are thought to be involved in the deposition of ECM. Liver fibrosis involves both quantitative and qualitative changes in ECM markers. Because some of the markers reflect fibrosis progression and others fibrosis regression, it is thought that a dynamic evaluation of ECM activity should be possible. Potential markers of fibrosis include products of collagen synthesis or degradation, enzymes involved in matrix biosynthesis or degradation, ECM glycoproteins, and proteoglycans/glycosaminoglycans. None of the currently available direct biomarkers completely fulfills the criteria for an ideal biomarker because none is liver specific and most are affected by changes in their metabolism, clearance, or excretion. But as fibrosis can occur in other organs of the body these markers are not specific for liver involvement in the process. And because of their determination is rather expensive and not every laboratory has

an opportunity to perform this these markers are not used in routine doctor's practice [1, 8].

In recent years there have been developed diagnostic indexes based on a combination of biochemical markers of liver fibrosis to improve the diagnostic value of various laboratory tests. The first group of the most widely used diagnostic panels was FibroMaks (BioPredictive, France).

Diagnostic panels FibroTest, FibroMaks and designed by French hepatologists and are an expert system based on the calculation of these biochemical parameters of blood: ALT, AST, gammaglutamiltranspeptidase (GGTP), total bilirubin, cholesterol, apolipoprotein A1, fasting glucose, gaptoglobin, α -2-macroglobulin, triglycerides [9].

FibroTest includes 2 calculation algorithms – Fibrotest for the diagnosis of liver fibrosis and Aktitest to assess the necroinflammatory activity, and the panel FibroMaks in addition includes diagnostic algorithms Steatotest to determine the stage of steatosis, Ashtest to determine the degree of activity of alcoholic steatohepatitis and Nashtest to evaluate the stage of nonalcohol steatohepatitis in patients with metabolic syndrome. According to the prospective study of liver biopsies its number decreased by 46% through the use FibroMaks [10].

Fibrotest has a lot of advantages over the other methods of liver diagnosis. FibroTest is a low invasive procedure – patient just needs to donate blood from vein. In biopsy the biomaterial is taken from only one area and there is a chance that the biopate will be obtained from a relatively healthy portion, as fibrosis affects the liver heterogeneously, and FibroTest allows you to make a comprehensive assessment of the entire liver condition. FibroTest detects functional disorders of liver even before the significant morphological defects are formed which makes possible finding of the earliest stages of fibrosis. FibroTest is indispensable when it is impossible to perform a biopsy on any clinical indications, such as disturbances of the blood coagulation system [9, 10].

In the pathology of metabolic syndrome in the absence of fibrosis and steatosis the observation is recommended every 1 – 2 years. In the presence of fibrosis, which is a consequence of steatosis or steatohepatitis an appropriate treatment and control is recommended every 3 – 4 months.

Application of FibroTest will give false-positive or false-negative results at acute hepatitis, extrahepatic cholestasis, Gilbert's syndrome, acute hemolysis, acute inflammation, in patients with liver transplants. Also FibroTest has disadvantages such as restrictions on carrying out the test in most of laboratories as they do not meet the requirements of the developer system and relative high cost of research [11].

Diagnostic panel SteatoScreen allows to detect the risk of development of fibrosis and/or steatosis in different groups of patients and can be considered as a routine test for initial diagnostics of histological activity of pathological processes in liver. SteatoScreen test consists of 1 calculation algorithm and is performed on the results of mathematical processing of the same 10 biochemical blood indexes which are required for the FibroTest.

Fibrometer is a system of tests that are also based on the calculation of the index using mathematical data of biochemical blood parameters. This system consists of three sets of tests that are used depending on the etiology of the disease.

Fibrometer A is performed for suspected alcohol etiology of the disease and is not used for the diagnosis in case of combined etiology. Fibrometer V is used in the presence of chronic viral hepatitis as an isolated pathology, and when combined with alcohol etiology and/or within NAFLD. Fibrometer S is applied in case of fatty liver disease and metabolic syndrome, as well as in combination with alcoholic etiology. The limitations of using this panel are the age under 18 years, acute hepatitis, kidney failure, pregnancy, and during treatment of liver disease [12].

The difference between the FibroTest and Fibrometer systems is there different visual evaluation (Pic. 1). The FibroTest is presented as a sole scale that represents the stage of the process, and the results of Fibrometer are presented in the form of double circular scales: the inner scale shows the stage of the process (by METAVIR system) and the outer line represents an index that indicates the amount fibrotic tissue. In both systems the results are performed from 0 to 1 (or in the percent) and indicate the volume of fibrotic tissue [11, 12].

FibroTest

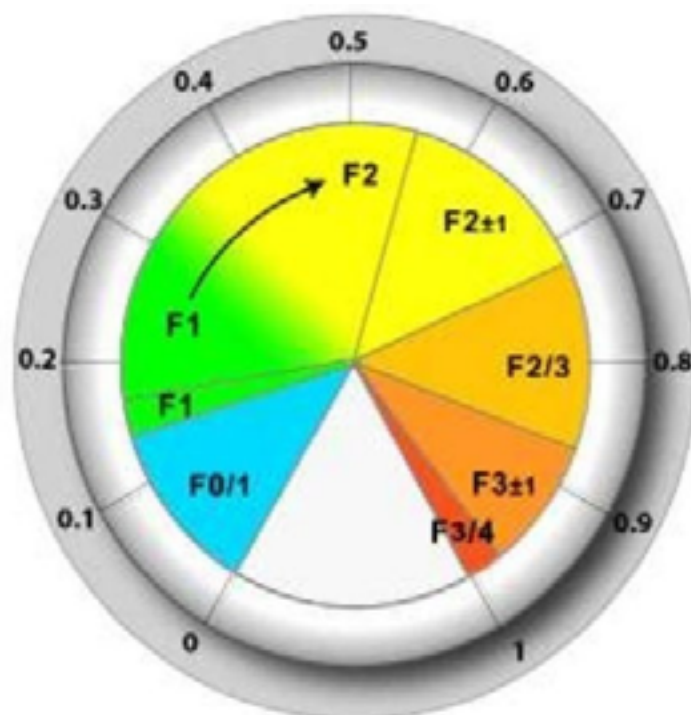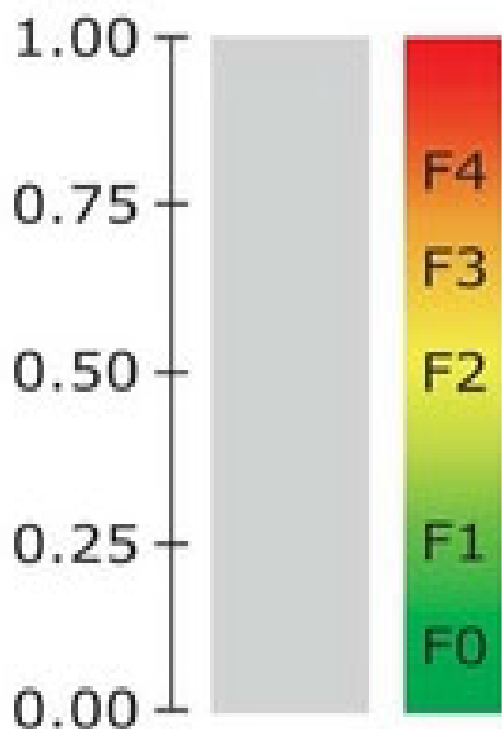


Fig.1. *FibroTest and Fibrometer scales*

There are some more tests for evaluation of morphological liver state. The scale CirrhoMeter allows to characterise the revealed fibrosis more accurately using the 3rd and the 4th stages by METAVIR. The scale InflammMeter allows a detailed assessment of necroinflammatory changes in liver. The scale shows the index and the stage of histological activity of the process [12]

Although liver biopsy remains the gold standard for assessment of liver fibrosis it does not meet all the requirements because of its potential for complications, the significant sampling

error and interobserver variability. Liver biopsy is not considered as a procedure used to monitor the treatment of patients and progression or regression of fibrotic processes. Assessment of liver fibrosis with multiple serum markers used in combination is sensitive, specific, and reproducible, suggesting they may be used in conjunction with liver biopsy to assess a range of chronic liver diseases. Noninvasive panels are suitable for assessing and particularly quantifying fibrosis but still not sensitive enough to measure small changes in the state of the ECM.

REFERENCES:

1. Diarmuid S. Diagnosis and Quantification of fibrosis/ Diarmuid S. Manning, Nezam H. Afdhal// Gastroenterology; 2008; vol. 134, issue 6. Pp. 1670-1681.
2. William M.C. Serum markers detect the presence of liver fibrosis: A cohort study/ William M.C. Rosenberg, Michael Voelker, Robert Thiel etc.// Gastroenterology; 2012; vol. 127, issue 6. Pp. 1704-1713.
3. Abdi, W. Sampling variability on percutaneous liver biopsy/ Abdi, W., Millan, J.C., and Mezey, E.// Arch Intern Med. 1979; vol. 139. Pp. 667-669.
4. Julien Vergniol. Noninvasive Tests for Fibrosis and Liver Stiffness Predict 5-Year Outcomes of Patients With Chronic Hepatitis C/ Julien Vergniol, julitte Foucher, Eric Terrebonne// Gastroenterology; 2010; vol. 140, issue 7. Pp. 1970-1979.
5. Goodman, Z.D. Progression of fibrosis in advanced chronic hepatitis C: evaluation by morphometric image analysis/ Goodman, Z.D., Becker, R.L. Jr, Pockros, P.J. et al.// Hepatology. 2007; vol. 45. Pp. 886-894.
6. Schiavon, L.L. Simple blood tests as noninvasive markers of liver fibrosis in hemodialysis patients with chronic hepatitis C virus infection/ Schiavon, L.L., Schiavon, J.L., Filho, R.J. et al.// Hepatology. 2007; vol. 46. Pp. 307-314.
7. Lieber, C.S. Aspartate aminotransferase to platelet ratio index in patients with alcoholic liver fibrosis/ Lieber, C.S., Weiss, D.G., Morgan, T.R. et al.// Am J Gastroenterol. 2006; vol. 101. Pp.1500-1508.
8. Afdhal, N.H. Evaluation of liver fibrosis: a concise review/ Afdhal, N.H. and Nunes, D. Am J// Gastroenterol. 2004; vol. 99. Pp.1160-1174.
9. Castera, L., Vergniol, J., Foucher, J. et al. Prospective comparison of transient elastography, Fibrotest, APRI, and liver biopsy for the assessment of fibrosis in chronic hepatitis C/ Castera, L., Vergniol, J., Foucher, J. et al.// Gastroenterology; 2005; vol. 128. Pp. 343-350.
10. Rossi, E. Validation of the FibroTest biochemical markers score in assessing liver fibrosis in hepatitis C patients/ Rossi, E., Adams, L., Prins, A. et al.// Clin Chem. 2003; vol. 49; Pp. 450-454.
11. Poynard, T. Meta-analyses of Fibrotest diagnostic value in chronic liver disease/ Poynard, T., Morra, R., Halfon, P. et al. BMC Gastroenterol. 2007; 7. Pp. 40.
12. Sebastiani, G. Stepwise combination algorithms of non-invasive markers to diagnose significant fibrosis in chronic hepatitis C / Sebastiani, G., Vario, A., Guido, M. et al. // J Hepatol. 2006; vol. 44. Pp. 686-693.