

NEW CRYOSURGICAL INSTRUMENTS IN TREATMENT OF TUMORS AND PURULENT DISEASES OF SKIN AND SUBCUTANEOUS FAT

UDC 615.832.97:616.5-002.3-006-72
Received 5.11.2011



M.Y. Averianov, D.Med.Sc., Professor, Head of the Department of General Surgery¹;
V.I. Kochenov, D.Med.Sc., Senior Research Worker, the Department of Operative Surgery
and Topographic Anatomy²;
V.V. Slonimsky, Surgeon, Polyclinic No.1³; Postgraduate, the Department of General Surgery¹

¹Kirov State Medical Academy, Karl Marx St., 88, Kirov, Russian Federation, 610000;

²Nizhny Novgorod State Medical Academy, Minin and Pozharsky Square, 10/1, Nizhny Novgorod,
Russian Federation, 603005;

³Railway Hospital, Kirov Station, Joint Stock Company "Russian Railway", Oktyabrsky Avenue, 151,
Kirov, Russian Federation, 610001

The aim of the investigation was the development, clinical testing, and the study of the results of using new cryosurgical instruments to treat benign neoplasms, skin and subcutaneous fat purulent diseases.

Materials and Methods. We studied the results of cryosurgical treatment of 447 patients with various skin diseases, among them 350 — with benign skin neoplasms, 97 — with pyoinflammatory diseases of skin and subcutaneous fat. For treatment of 38 patients we used self-designed instruments.

Conclusion. The use of new instruments in cryosurgery of patients with skin and subcutaneous fat diseases enabled to reduce significantly traumatism in surgical procedures, increase the efficiency of cryosurgery, optimize the process of wound healing, reduce disability time and recurrence rate.

Key words: cryosurgery; cryodestruction; benign neoplasms; purulent diseases of skin and subcutaneous fat.

Acute and chronic infections of skin and subcutaneous fat, posttraumatic and postoperative wound abscesses occur in 35–45% of patients. The frequency of visits to a surgeon for primary medical aid in this pathology reaches 70% [1–5].

Currently, the prospects for further development of ambulatory surgery based on the usage of modern less traumatic techniques raise no doubts. It is confirmed by the fact that along with traditional departments of surgery in polyclinics, there is the expansion of outpatient care in ambulatory surgical centers and one-day surgical hospitals at multi-field medical treatment facilities [6]. The problems of high-efficiency outpatient treatment of soft tissue purulent infection are of primary importance since there should be rationally combined conservative therapy, complete operative interventions, and timely determination of indications for hospital admission [7].

In recent decades there is an increasing number of studies concerned with the therapeutic effect of various physical factors on a wound process. Their usage serves to improve the efficiency of surgical treatment. The effect of physical medicine is based on both mechanical removal of devitalized tissues, and direct antibacterial effect [2, 8, 9].

Local cryotherapy is one of the additional physical methods of treating septic wounds, and it is relevant due

to antibiotic resistance of many bacterial strains. Liquid nitrogen application and necrotic area freezing enable to perform bloodless and painless necrectomy, and local hyperemia and inflammation developing after thawing of tissues have a stimulating effect on a wound process course resulting in high regenerative rate, organotypic character of regeneration, and the efficiency of this technique [10–13].

The aim of the investigation was the development, clinical testing, and the study of the results of using new cryosurgical instruments to treat benign neoplasms, skin and subcutaneous fat purulent diseases.

Materials and Methods. Over the period from 2009 to 2012 in surgery of Polyclinic No.1 of Railway Hospital (Kirov Station, Joint Stock Company "Russian Railway") we used cryotherapy for the treatment of 447 patients with various skin and subcutaneous skin diseases including 197 male (44%) and 250 female (56%). The patients' age varied from 18 to 70 years, mean age was 45.3±9.5 years.

Among 350 patients with skin neoplasms, 282 patients underwent a single operation, and 68 patients – multiple surgeries for previous undetected neoplasms of other localizations. Benign skin neoplasms included the following clinical entities: papillomas — 152 patients (43.4%), virus verrucas — 130 (37.14%), plantar warts — 40 (11.4%), hemangiomas — 15 (4.3%), pigmented nevi — 8 (2.3%), cheloid scars — 5 (1.43%).

For contacts: Slonimsky Vladimir Vladimirovich, phone. +7 905-870-24-29; e-mail: vladimirvsl.77@mail.ru

Exposure time in all cases of cryotherapy was from 30 to 45 s in every point depending on the neoplasm size. Cryodestruction was performed once if tumor size was up to 2.5 cm in diameter (Table 1).

Complex cryosurgical treatment of purulent skin and subcutaneous fat diseases was performed using standard instruments — in 59 patients (treatment group), and conventional surgical techniques were used in 57 cases (control group) (Table 2). The patients' age in both groups varied from 18 to 55 years. Mean age was 38.9±8.9 years.

For cryosurgical treatment of the main group patients we used standard cryodestruction instrument sets with interchangeable metal tips designed for contact procedure. Cryodestruction was used once. Exposure time was 30–45 s in every point resulting in complete freezing of the pus cavity walls at a depth of 1–2 mm.

Microflora in the suppurative area in the main and control groups was studied twice: at first — immediately after abscess opening, and then — 24 h later. The samples were taken from the deepest wound layers followed by culture test for aerobic and anaerobic microorganisms, and transported using sterile Amies medium.

For treatment of 38 patients with neoplasms and pyoinflammatory diseases of skin and subcutaneous fat self-designed instruments were used.

One of such instruments was a cryoclamp made on the basis of Kocher's clamp with sphere-shaped tips of different diameters (Fig. 1), which enable to use an instrument for both cryocompression destruction and cryoapplication for the purpose of sanitation and destruction of walls of pathological cavities [14].

Operative interventions using a cryoclamp were performed in 21 patients including 4 (19%) patients with papilloma, 2 (9.5%) patients — with plantar warts, 3 (14.3%) — with hemangioma, 5 (23.8%) — with festered atheroma, 7 (33.3%) — with furuncular abscess.

Immediately prior to the procedure, the tip of a cryoclamp was placed into thermos flask with liquid nitrogen till complete cooling that was indicated by stopping gas bubbling from liquid cryogen. After abscess opening under

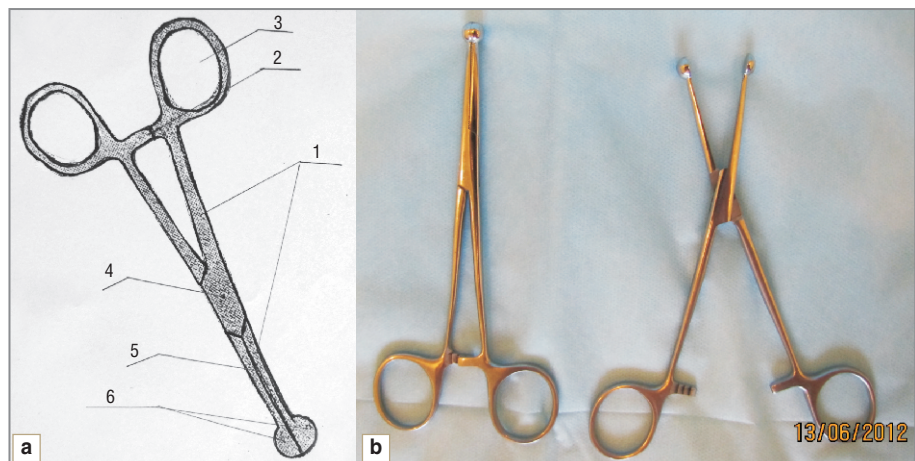
Table 1
Cryodestruction time according to the neoplasm size

Neoplasm diameter, cm	Exposure time, s	Number of procedures
Up to 0.5	30	Once
0.5–1	35–40	Once
1–2	45	Once
2.5 and more	Over 45	Staged cryodestruction

Table 2
Distribution of patients according to clinical entities and average disability periods

Clinical entities	Disability period, days			
	Treatment group (cryosurgical technique)		Control group (surgical management)	
	Number of cases	Average disability periods	Number of cases	Average disability periods
Festered atheroma	9	7.2±1.2	9	10.60±2.06
Infected corn	5	6.40±1.14	4	10.3±1.7
Suppurative wound	7	9.70±2.42	8	11.40±2.06
Furuncular abscess	15	6.60±1.63	16	10.80±1.94
Whitlow	8	6.80±1.48	7	11.20±1.57
Hydradenitis	11	8.50±1.75	10	11.30±2.21
Infected ingrown nail	4	8.80±2.36	3	12.70±2.08
Total	59	7.60±1.98	57	11.10±1.92

Fig. 1. A cryoclamp for compression cryoablation and cryoapplication: a — scheme: 1 — branch; 2 — clamp with a catch; 3 — ring; 4 — screw to fix a branch; 5 — incisal surface of the branch; 6 — a sphere-shaped tip; b — an instrument in operating condition



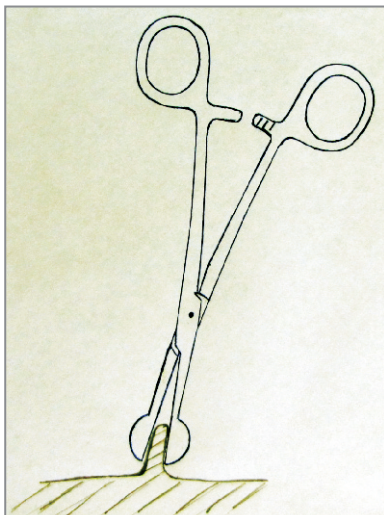


Fig. 2. Cryocompression destruction of papilloma (scheme)

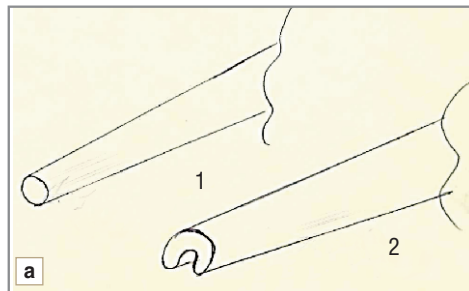


Fig. 3. A tip for cryotherapy apparatus: *a* — a scheme of a standard (1) and a horseshoe (2) tips; *b* — a tip in operating condition and nonassembled

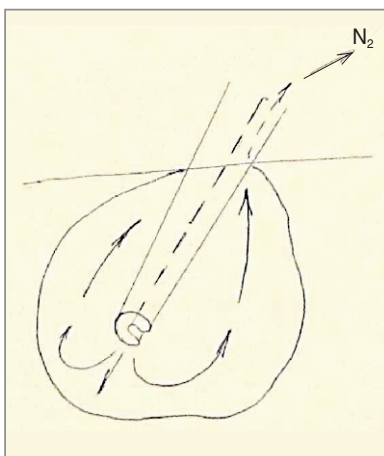


Fig. 4. The treatment of the pus pocket with a horseshoe tip. The arrows indicate the nitrogen vapor movement into the cavity through the opening in the tip and back along the inner groove

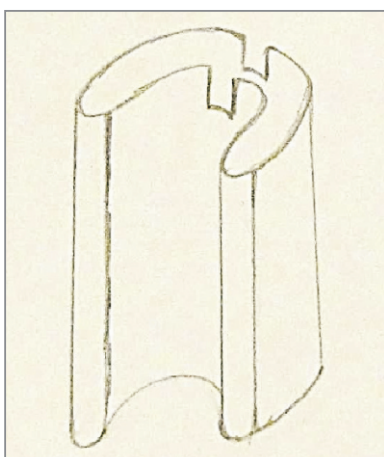


Fig. 5. A modified horseshoe tip

local anesthesia and the cavity sanitation, we treated the internal surface of the cavity by closed ends of a sphere-shaped tip.

The procedures to remove benign skin neoplasms using a cryoclamp were performed with no pre-anesthesia (Fig. 2).

The treatment of pus cavities having convoluted pockets

or leaks by standard instruments is known to be frequently accompanied by certain difficulties due to the adhesion of walls and the tip surface that prevents normal cryogen circulation in the cavitory lesion and cryogen excess removal, and needs large or additional incisions. These factors turned out to be the reason for introducing innovative technology concerning the design of standard tips. To optimize the treatment of pus cavities, we developed a new tip for a cryotherapy apparatus [15]. A horseshoe-shaped instrument enabled to level undesirable effects: cryogen excess is removed from the cavity along a special groove (Fig. 3).

After treating the pus cavity, leak, or a fistulous passage by nitrogen vapor through a tip (Fig. 4), we carried out a single destruction of the cavity walls by a sphere-shaped cryoapplicator. To eliminate an undesirable effect of adhesion of the instrument with an internal surface of the cavity we used a modified horseshoe tip: it had flutes on semispheres, through which cryogen was freely withdrawn even if an instrument was in full contact with the cavity walls (Fig. 5).

A horseshoe tip was used for cryoablation of pus pocket walls in 7 patients with festered atheromas (41.2%) and in 10 patients with furuncular abscesses of various localizations (58.8%).

Results and Discussion. The comparative assessment of microorganism cultures showed that the use of cryosurgical techniques in the management of patients with pyoinflammatory diseases of skin and subcutaneous fat contributes to significant reduction of the number of viable infectious agents in incisional wound compared to usual surgeries (Table 3).

All patients made a full recovery at the stage of ambulatory treatment, though average disability periods in the main and control groups were 7.60 ± 1.98 and

11.10±1.92 days respectively, p<0.05 (See Table 2). The treatment of neoplasms and purulent surgical diseases using a cryosurgical technique resulted in a good cosmetic effect (Fig. 6).

Cryosurgical technique is effective in the management of various benign skin diseases. Recurrences after cryoablation were revealed in patients with virus verrucas (4 recurrences for 130 operations, 3.1%) and papillomas (1 recurrence for 152 operations, 0.7%). The recurrence rate was 1.8%. The management of nevi, keloids and hemangiomas was recurrence-free.

The performed researches showed that the use of the proposed cryoclamp with a sphere-shaped tip enabled to increase the volume of outpatient surgical care and perform a wide range of operative interventions:

- cryocompression destruction of virus verrucas, papillomas, basaliomas, hemangiomas, inflammatory hypertrophic granulomas, scleronychia, hemorrhoidal tumors, condylomas;

- cryoapplication to remove pigmented nevi, telangiectasias, cheloid scars, erosions;

- sanitation and destruction of the walls of pathological cavities: furuncles, carbuncles, abscesses, septic wounds with necrotic areas, small tumor cavitations, atheromas, etc.

The use of the designed horseshoe tip of a cryotherapy apparatus and its modified version enables:

- to provide unhampered delivery of cryogen to pathological cavities;
- to optimize cryogen circulation in a wound;
- to remove easily excessive cryogen;

Table 3

Quantitative estimation of infectious agents in a wound

Infectious agent	The first day	The second day	
		without cryodestruction	with cryodestruction
<i>Staphylococcus aureus</i>	10 ⁶ -10 ⁷	10 ⁴ -10 ⁵	10 ² -10 ³
<i>Staphylococcus intermedius</i>	10 ⁶ -10 ⁷	10 ⁴ -10 ⁵	10 ² -10 ³
<i>Peptostreptococcus</i>	0-10 ⁶	0-10 ²	0
<i>Porphyomonas asaccharolytica</i>	0-10 ⁶	0-10 ³	0
<i>Prevotella intermedia</i>	0-10 ⁴	0-10 ²	0
<i>Fusobacterium nucleatum</i>	0-10 ⁵	0-10 ⁴	0
<i>Bacteroides</i>	0-10 ³	0	0

- to reduce the traumatic effect of an operation due to the reduced incision;
- to improve cosmetic effect.

Conclusion. The use of cryosurgical techniques in the management of neoplasms and pyoinflammatory diseases of skin and subcutaneous fat in all cases significantly reduce the traumatic effect of an operation compared to conventional surgeries, and make it possible to achieve absolute recovery of patients at the stage of outpatient therapy, and reduce average disability periods.

The use of designed instruments significantly helps the treatment process of pus cavities and fistulous tracts of various shapes and sizes, improves the treatment quality without exposure time extension, and optimizes the healing process. The destruction of skin neoplasms using a sphere-shaped cryoclamp/applicator of the proposed design increases the efficiency of cryosurgery, results in a good cosmetic effect, and reduces the recurrence rate.

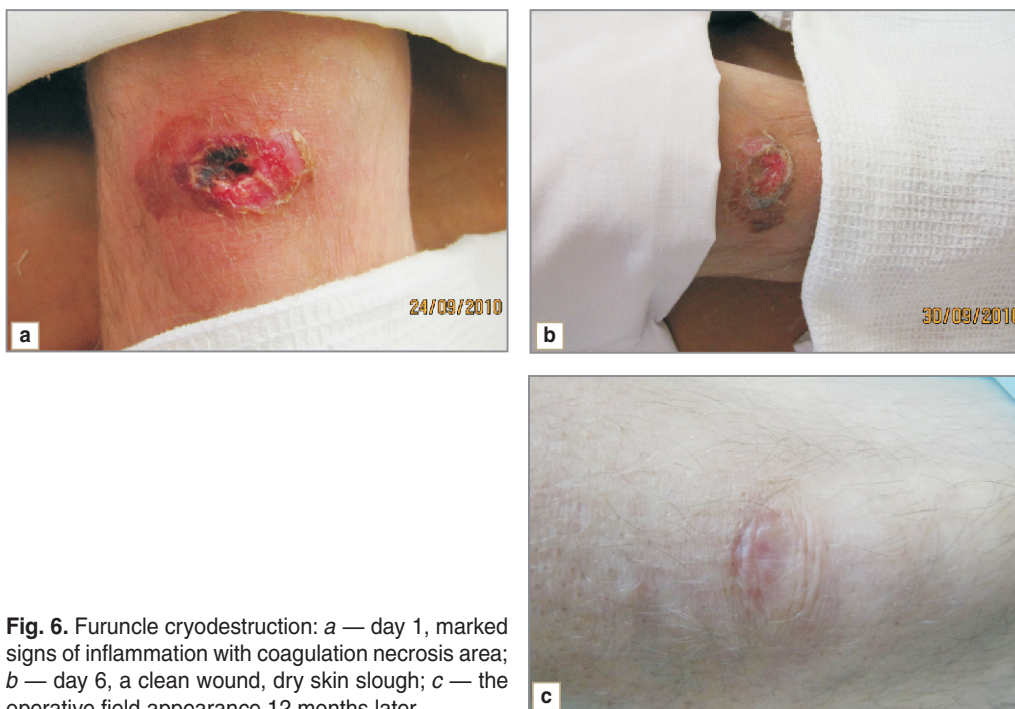

Fig. 6. Furuncle cryodestruction: a — day 1, marked signs of inflammation with coagulation necrosis area; b — day 6, a clean wound, dry skin slough; c — the operative field appearance 12 months later

References

1. Blatun L.A. Mestnoe medikamentoznoe lechenie ran [Local drug treatment of wounds]. *Khirurgiya — Surgery* 2011; 4: 51–59.
2. *80 lektsiy po khirurgii* [80 lectures on surgery]. Pod obshchey red. Savel'eva S.V. [Savel'ev S.V. (editor)]. Moscow: Literra; 2008; 912 p.
3. Makarova N.P., Grigor'ev N.N., Chernyad'ev S.A., Bersenev S.G., Zasorin A.A., Sandalov E.Zh. Problema gnoynovospalitel'nykh zabolevaniy myagkikh tkaney u voennosluzhashchikh [The problem of pyoinflammatory soft tissue diseases in military personnel]. *Voенно-медицинский журнал — Military Medical Journal* 2010; 9: 53–57.
4. Nessim C., Bensimon C.M., Hales B., Laflamme C., Fenech D., Smith A. Surgical site infection prevention: a qualitative analysis of an individualized audit and feedback model. *J Am Coll Surg* 2012 Dec; 215(6): 850–857.
5. Ng R.S., Chong C.P. Surgeons' adherence to guidelines for surgical antimicrobial prophylaxis — a review. *Australas Med J* 2012; 5(10): 534–540.
6. Vorob'ev V.V., Stroy V.N., Sivolodskiy Yu.E., Shilyaev A.V., Poggenpol' V.S., Ayrapetyan N.E. Vozmozhnosti i perspektivy dnevnykh statsionarov v lechenii khirurgicheskikh infektsiy [The possibilities and prospects of day patient departments in the therapy of surgical infections]. *Ambulatoynaya khirurgiya — Ambulatory Surgery* 2010; 2: 16–18.
7. Andrianova L.V., Rogozin V.V. Profilaktika gnoynoy infektsii v otdelenii poliklinicheskoy khirurgii [Prevention of purulent infection in the department of polyclinic surgery]. *Ambulatoynaya khirurgiya — Ambulatory Surgery* 2010; 84–85.
8. Lee S.Y., Niikura T., Miwa M., et al. Negative pressure wound therapy for the treatment of infected wounds with exposed knee joint after patellar fracture. *Orthopedics* 2011 Jun 14; 34(6): 211–214.
9. Onigbinde A.T., Adedoyin R.A., Ojoawo O.A., et al. Effects of ultraviolet radiation (type B) on wound exudates, appearance and depth description. *Technol Health Care* 2010; 18(4–5): 297–302.
10. Korolev Yu.V., Kochenov V.I., Tsybusov S.N. Kriokhirurgicheskoe lechenie furunkulov s primeneniem MMLF v magnitnom pole. V kn.: *Meditinskaya kriologiya. Vyp. 5. Mezhdunarodnyy sbornik nauchnykh trudov*. [Cryosurgical treatment of furuncles using SMPF in magnetic field. In: Medical cryology. Issue 5. International collection of scientific papers]. Pod red. Kochenova V.I. [Kochenov V.I. (editor)]. Nizhny Novgorod: «onKolor»; 2003; p. 134–142.
11. Korzhikova S.V., Savchenkova I.P. Podkozhno-zhirovaya tkan' cheloveka, podvergnutaya nizkotemperaturnomu shoku, kak istochnik zhiznesposobnoy kletochnoy populyatsii s kharakteristikami mul'tipotentnykh mezenkhimnykh stromal'nykh kletok [Human subcutaneous fat tissue exposed to low-temperature shock as the source of a viable cell population with the characteristics of multipotent mesenchymal stromal cells]. *Tsitologiya — Cytology* 2010; 8 621–627.
12. Chizh N.A., Sandomirskii B.P. Cryosurgery, reloading and renewal. *Klin Khir* 2011 Jun; 6: 53–55.
13. Liu J., Deng Z.S. Nano-cryosurgery: advances and challenges. *J Nanosci Nanotechnol* 2009 Aug; 9(8): 4521–4542.
14. Averianov M.Yu., Kochenov V.I., Slonimskiy V.V. *Kriozakhvat dlya kompressionnoy kriodestruksii i krioplikatsii* [Cryo-forceps for compression cryodestruction and cryoapplication]. Patent №111421 RF. МПК: А61В18/02. 2011.
15. Averianov M.Yu., Kochenov V.I., Slonimskiy V.V. *Nakonechnik dlya kriodestruktora* [Tip for cryodestructor]. Patent №109402 RF. МПК: А61В18/02. 2011.