

Application of Reperen Miniplate for Minor Calvarium Defect Plasty in Intracerebral Hematoma Removal

DOI: 10.17691/stm2015.7.2.23

Received June 9, 2014



S.E. Tikhomirov, PhD, Neurosurgeon

Pavlovo District Hospital, 1a, 8 Marta St., Pavlovo, 606108 Nizhny Novgorod Region, Russian Federation

There has been presented a case of successful application of a miniplate made of Reperen material (Russia) for primary plasty of a minor calvarium defect in minimally invasive brain surgery. The stages of the proposed cranioplasty technique are described. The invented miniplates made of this material (round-shaped, 3.0; 3.5; 4.0 cm in diameter and 1.0 mm thick) enable rapid closure of the bone defect without any additional adjustment.

Key words: cranioplasty; Reperen; haemorrhagic stroke.

Modern brain imaging methods enable to accurately locate and evaluate the hemorrhagic substrate density in brain traumas as well as acute cerebrovascular disorders. Consequently, there appeared an opportunity to target exactly the hemorrhagic substrate according to the preoperatively mapped scelerotopic lines or using computer-assisted frameless neuronavigation. The craniotomy size in this case can sometimes be limited to that of a burr hole, but often a wider opening of 2.0 to 4.0 cm in diameter is required. Osteoplastic craniotomy for creating minor accesses is not very convenient as making 3 to 4 burr holes with a bone flap being subsequently cut out is rather time-consuming, and minor accesses are usually performed by means of bone resection from the burr hole. Thereby a small cranial defect is formed in a patient.

As an alternative, cutting out a round-shaped bone flap with a crown burr [1, 2] is proposed. An absolute advantage of this method is the ease of making the required access with the possibility to place the bone flap back into position on completing the operation. However, not many hospitals have such tools available.

The small cranial defect formed by the resection method does not affect the brain pathologically but a subjective sensation of unprotected brain prevents the patient from complete rehabilitation.

Six operative interventions producing trephine

openings up to 4.0 cm diameter and the following plasty with Reperen miniplate were performed in Pavlovo Central District Hospital during December 2013 to June 2014. In 5 cases the surgery was carried out for hypertensive intracerebral hematoma, in 1 case for symmetrical intracerebral hematomas of traumatic origin. Here is the description of one of such cases.

A male patient aged 49 developed an acute disease in February 2014. Figure 1 presents preoperative computed tomogram. Surgical intervention was performed on day 5 due to the worsening neurological status: depression of consciousness up to sopor. Preoperative mapping of the intracerebral hematoma projection on the calvarium was performed according to scelerotopic reference lines (Figure 2). Access was made over superior temporal gyrus. Soft tissues were dissected using 5.0 cm long linear vertical incision. A burr hole was made and widened by way of resection with formation of a trephine opening 3.0 cm in diameter. Once the dura mater was opened, encephalopuncture was performed, lysed blood was partially aspirated through a puncture needle. Then an encephalotomy access about 1.5 cm in diameter was made through the puncture channel, solid blood clots aspirated (Figure 3). The dura mater was sutured. Then a hemostatic foam was epidurally placed and Reperen miniplate 1.0 mm thick and 3.5 cm in diameter was applied on the bone without

For contacts: Tikhomirov Sergey Evgenievich, e-mail: 9519191113@mail.ru

additional fixation (Figure 4). The soft tissues were then closed over the plate in layers. Thus the plate appeared to be fixed between the bone and the superjacent soft tissues. No complications due to implant mounting were observed. In the post-operative period positive dynamics was seen in both neurological status and control brain computed tomography findings (Figure 5).

Informed consent to use the data was received from the patient.

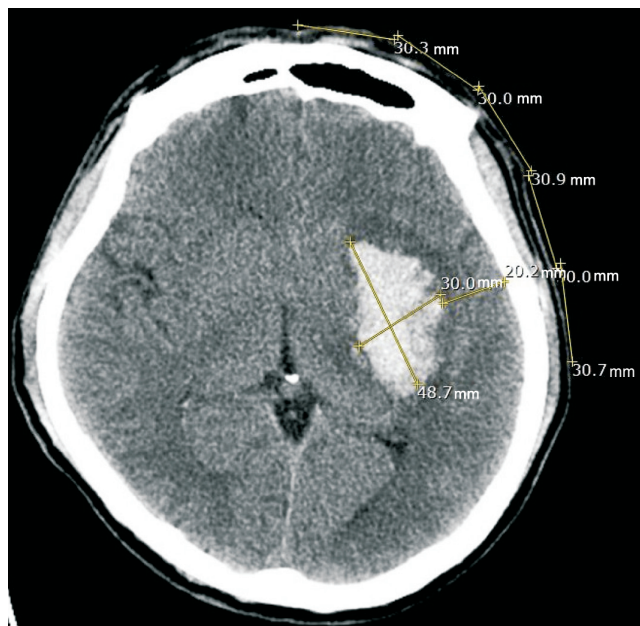


Figure 1. Pre-operative computed tomogram of the male patient aged 49. The intracerebral hematoma size and the distance to the cerebral cortex were measured, hematoma projection on the calvarium was calculated

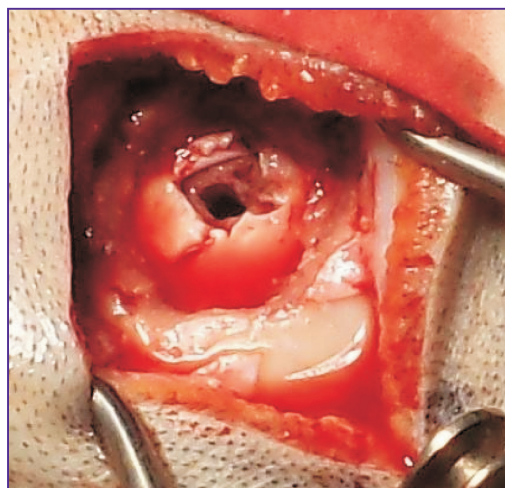


Figure 3. Encephalotomy access about 1.5 cm diameter was made, solid blood clots aspirated

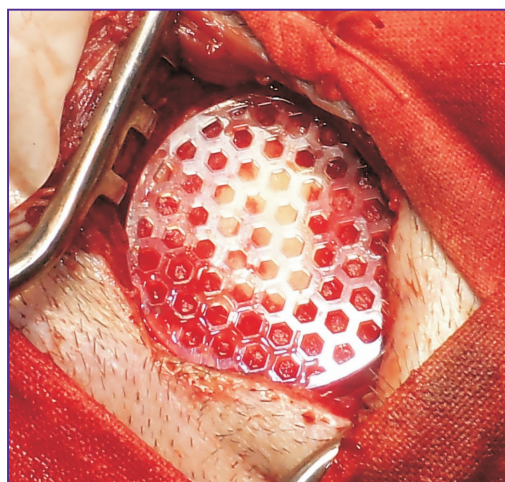

Figure 4. Hemostatic foam was placed epidurally, and Reperen miniplate was applied on the bone

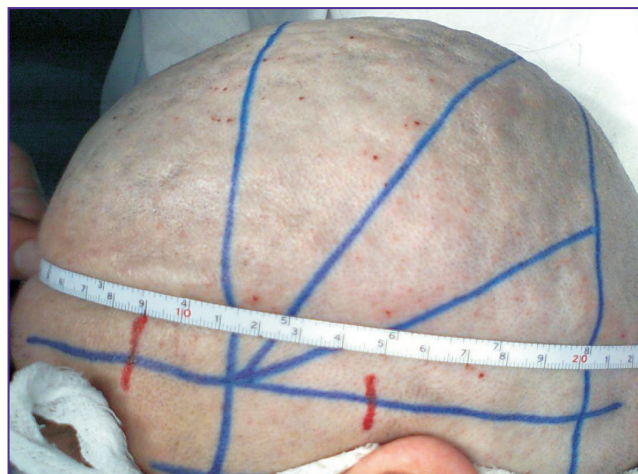

Figure 2. Initial mapping was made according to the hematoma projection on the calvarium, also projection of superior temporal gyrus was built using Kronlein scheme

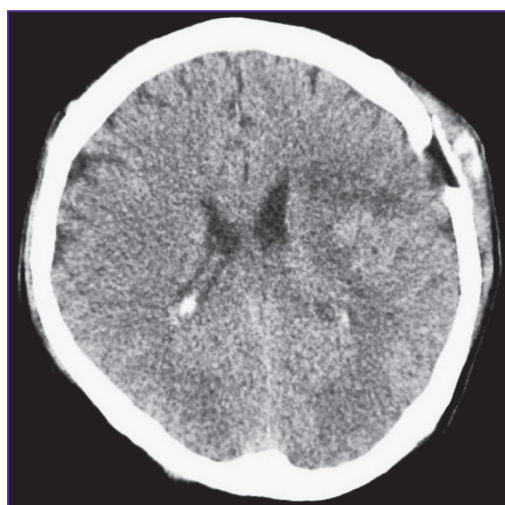


Figure 5. Post-operative computed tomogram of the male patient aged 49. Hemorrhagic substrate evacuation is almost complete. The Reperen plate tightly adjoins the bone defect margins

2.0 mm thick Reperen plates for cranioplasty have been used in neurosurgery since 2006. Experimental and clinical research proved biologic inertness of this material [3–7]. For plastic reconstruction of small defects it was also possible to use standard-size plates, cutting out the necessary fragment. But the procedure is time-consuming, most of the material remains non-demanded. Besides, 2 mm thickness appears to be not very convenient for closing minor defects. The invented round-shaped Reperen plates 3.0; 3.5; 4.0 cm in diameter and 1.0 mm in thickness enable rapid closure of a bone defect without any additional adjusting. The implant is fixed between the bone and the overlying soft tissues. Connective tissue fibers penetrating through multiple perforation holes of the plate provide “biologic” fixation of the implant [3, 7].

With minimally invasive evacuation of intracerebral hematomas the formed trephine opening is not big in size, yet a cosmetic defect remains as regenerative capacity of calvarium bones is rather low and bone defects more than 1.5 cm in diameter do not close by themselves [8, 9]. The presented plasty method using miniplates made of home-produced Reperen material enables to easily eliminate the emerging cosmetic defect.

Study Funding. This study was not supported by any financial sources.

Conflict of Interests. The authors have no conflict of interests to disclose.

References

1. Koksharev I.V. Application of modified crown burrs for craniotomy. *Kreativnaya onkologiya i khirurgiya* 2011; 1, <http://eoncoursurg.com/primenenie-modifitsirovannyh-koroncha> (accessed: 01.06.2014).
2. Samoshenkov G.S., Romanenkov V.M., Samoshenkov A.G., Panchenko V.P. A device for cranial trepanation. *Nejrohirurgia* 2002; 2: 62–63.
3. Tikhomirov S.E., Tsybusov S.N., Balmasov A.A., Vasyagina T.I. Experimental justification of calvarium defect plasty with reperen material. *Morfologiceskie vedomosti* 2009; 3: 236–237.
4. Tikhomirov S.E., Tzibusov S.N., Kravetz L.Ya. Using of the material “Reperen”[®] for plastics of defect of skull fornix (experimental and clinical results). *Sibirskij medicinskij zurnal (Irkutsk)* 2010; 2: 121–124.
5. Tikhomirov S.E., Tsybusov S.N., Kravets L.Ya., Fraerman A.P., Balmasov A.A. Plasty of the base of the skull defects and dura mater with the reperen’s new polymer material. *Sovremennye tehnologii v medicine* 2010; 2: 6–11.
6. Tikhomirov S.E. Plasty of defects of calvarium with “Reperen” material. *Rossiyskiy neyrokhirurgicheskiy zhurnal im. professora A.L. Polenova* 2010; 3: 52–56.
7. Tikhomirov S.E., Tsybusov S.N., Kravets L.Ya. Soft tissue response to grafting of polymer implant “Reperen”. *Nejrohirurgia* 2012; 3: 45–52.
8. Kravchuk A.D. *Rekonstruktivnaya i maloinvazivnaya khirurgiya posledstviy i oslozhneniy cherepno-mozgovoy travmy*. Dis. ... dokt. med. nauk [Reconstructive and minimally invasive surgery of cerebrocranial trauma complications and consequences. Dissertation for the degree of Doctor of Medical Science]. Moscow; 2000.
9. Levchenko O.V. Modern methods of cranioplasty. *Nejrohirurgia* 2010; 2: 5–13.